

# The Management of the Nonfunctional Hand—Reconstruction vs. Prosthesis

STERLING BUNNELL, M.D.<sup>1</sup>

AN THE course of routine practice, the orthopedic surgeon is frequently confronted with the task of dealing with hands that are damaged by trauma or disease or that are otherwise nonfunctional owing to any of a variety of causes. In all such cases, he is called upon to decide whether or not to undertake amputation of parts of the hand or amputation through the wrist, with the expectation of later applying a suitable prosthesis, or whether, with the prospect of long-continued treatment and the possibility of ultimate failure, to attempt surgical construction of a functional hand from such anatomical elements as can be saved. The considerations involved are many and varied, and rarely do two cases resemble each other in more than a remote way. Each individual case must therefore be evaluated on the basis of its own merits.

There has been in the past dozen years a great advancement in the development of hand prostheses, so that in the case of major hand problems one might be inclined to choose wrist disarticulation over attempts at surgical reconstruction. But during the same period surgical reconstruction also has advanced remarkably, so that in judging any individual case there should be a careful analysis as to which procedure is the better to follow. Doing so usually results in a sort of compromise—reconstruction, if reasonably possible, being chosen first, a prosthesis being applied when proven necessary, major amputation being considered only as a last resort. It is the purpose here to attempt to extract from many years of clinical experience with hand surgery

certain general principles that may offer guidance in making the choice. Generally, the current rule of "save all length possible," now applicable at most other levels of amputation, is applicable in the case of damaged hands also.

The fundamental difference between a reconstructed hand and any present-day hand prosthesis lies in the absence of direct sensation in the latter. Although the wearer of a modern hook or artificial hand may receive indirect sensory impulses through shoulder harness or cineplastic muscle pin, the conventional arrangement constitutes only a crude and inefficient signal system which must be supplemented and directed by sight. A hand prosthesis is of little use in the dark. In contrast, there is the exquisite appreciation we receive from the normal hand by feeling. By light touch, coarse touch, response to heat or cold, and compass-point discrimination, we appreciate texture, and by muscle, joint, and tendon sense we appreciate size and shape. By combining these sense impressions in our cerebral cortex in the opposite parietal lobe, we can identify from memory an object held in the hand. This is stereognosis, a phenomenon replaced by no artificial hand now available. To quote Kirk (6), "No hand is so badly crippled that, if it is painless, has sensation, and strong prehension, it is [not] far better than any prosthesis." This being the case, it is generally desirable to preserve any and all hand structures that can reasonably be counted on to have adequate nerve and blood supply. Eventual application of a prosthesis may or may not be indicated, depending upon individual circumstances and the particular demands of occupation.

<sup>1</sup> 516 Sutter Street, San Francisco 2, Calif.

Before considering any hand amputation, then, one should weigh well the possibility of surgical reconstruction, especially with the idea of restoring natural sensation and strong prehension. Whenever reasonably feasible, surgical reconstruction of a damaged hand or arm should be attempted first. Often the result will be such that a prosthesis will not be necessary. In any case, a reconstructed hand stump is apt to be much better adapted to application of a prosthesis. As a matter of fact, reconstruction and use of a prosthesis are so interrelated that they should be considered together in each individual case. Every useful part of a limb, and every bit of skin that has sensation, should be preserved, thus giving more useful material for reconstruction and, finally, for the fitting, if necessary, of a prosthesis.

Reconstruction may often be done in one operation; in other cases multiple operations are required over a period of a month to a year. But considering that the goal is to provide a useful hand for the remainder of an individual's life, it seems worth while. Nevertheless, it should not be undertaken unless there is reasonable assurance that a good practical result can be obtained.

#### METHODS OF SURGICAL RECONSTRUCTION

Although the hand does the work, the arm places and innervates the hand. Accordingly, if any particular hand is to be truly useful, it is necessary to have good shoulder, elbow, and wrist function and also good pronation and supination—half furnished by the shoulder and half below the elbow. Because they supply the hand, the nerves of the arm are particularly important. In the hand itself there should be a good quality of sensation as well as mobile units that can work against each other with at least a pinch grasp or hook action to simulate normal prehension.

Hands coming in for repair usually evidence partial amputations, stiffening in the position of nonfunction, flexion contracture from scar formation, malalignment of bones, loss of motion from injury to tendons and nerves, loss of sensation from injury to nerves, ischemic contracture, or painful states from vasomotor causes or from tender neuromata. Usually the

surgeon's problem is composite, dealing with cover, joints, bones, nerves, and tendons.

For each of these conditions there is much that can be done surgically (2). For partial amputation, clefts between digits may be deepened, and digits can be built out and made to appose each other. Tender stumps may be corrected. For stiffening in the position of nonfunction, the joints may gradually be drawn around to the position of function by spring or elastic splinting and can be mobilized surgically. Scar tissue of flexion contracture can be replaced by good pliable skin giving good cover and improving nutrition. Malalignment of bones may be corrected so that the mechanics of tendon action are correct. Substitute thumbs may be formed. Tendons and nerves may be repaired or transferred, or new ones may be furnished. Ischemic contracture can be relieved so that a hand thus affected can regain some function. Painful states may be corrected by sympathectomy, and tender neuromata may be removed.

#### PARTIAL AMPUTATION"

Arm stumps resulting from amputation through the wrist or through the carpometacarpal joint, or those without the thumb and with amputation through the metacarpals or proximal phalanges, require a prosthesis (Fig. 1). Hands retaining a good thumb working against one or more fingers (as in Figure 2), or even against a surgically constructed post (as in Figure 3), do not. Sometimes the usefulness of a sound thumb may be much enhanced by surgical procedures conducted on other remaining hand parts (as for example in Figure 4). Other partial hands (like those shown in Figures 5 and 6 for example) when reconstructed usually are more functional than a prosthesis. Some with a partial hand amputation use remnants of the hand for fine work and a prosthesis for heavy work.

In partial amputations it is best, if possible, to retain the metacarpal heads and hence the full width of the palm for firm grasp of tools, but the metacarpal head of an index or of a little finger that has been amputated through the metacarpophalangeal joint is best beveled off so that it will not snag on entering a pocket. The metacarpal of an index or little

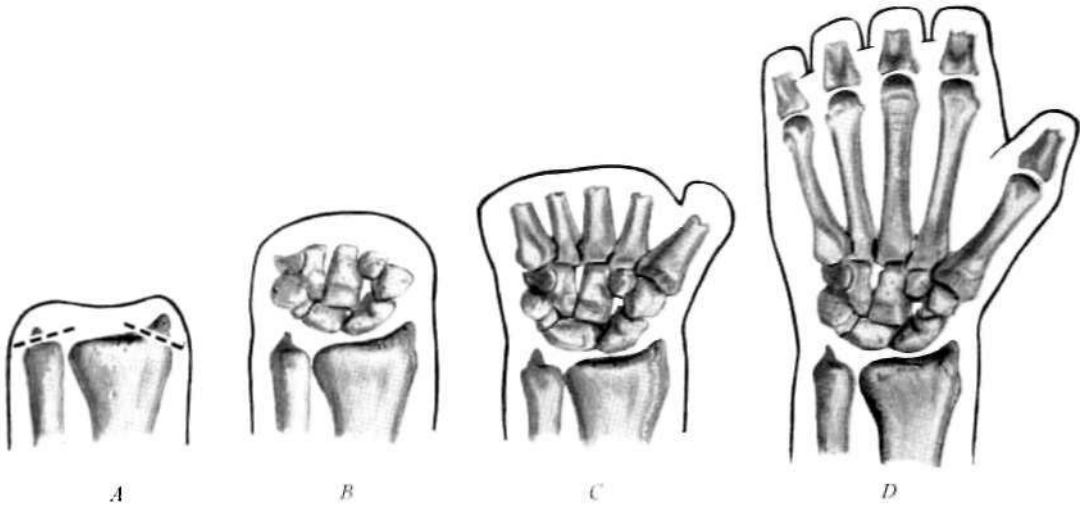


Fig. 1. Levels of hand amputation requiring prosthesis. *A*, Wrist disarticulation, including removal of the distal prominences of radius and ulna; *B*, amputation through the carpometacarpal joint; *C*, transmetacarpal amputation; *D*, amputation through all proximal phalanges. In *B*, some useful wrist motion may be retained. In *C*, hand remnant may be used as a wrist motor to power a prosthesis or simply to point one. In *D*, hand stump may be made to work against some prosthetic device, residual sensation offering a substantial advantage over *A*, *B*, or *C*.

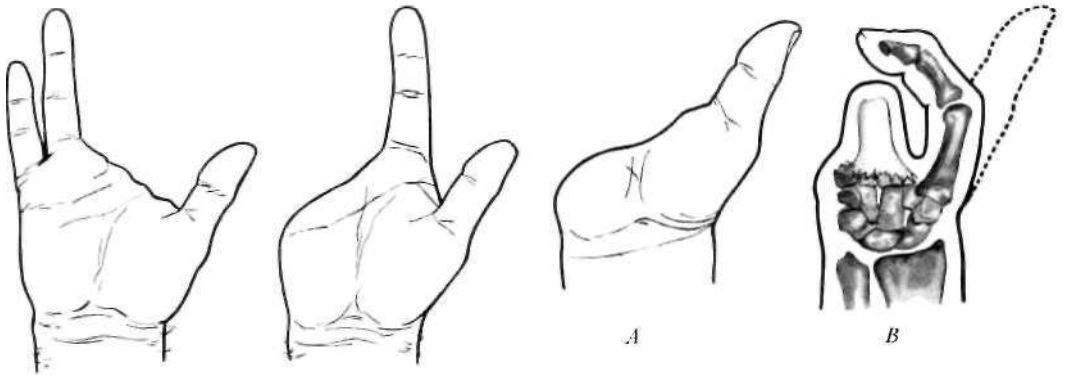


Fig. 3. Partial hand (*A*) and result of reconstruction (*B*), no prosthesis needed. When, in the absence of all the fingers and much of the palm, a good thumb remains, it is possible, by means of pedicle and bone graft, to build up a post for the thumb to appose. Function thus obtained is likely to be better than that to be had from a hand substitute.

Fig. 2. Examples of partial hands requiring no prosthesis. When the thumb can work against one or more fingers, function usually is better than can be obtained with a hand substitute.

finger off through the shaft is best removed obliquely at its base (Fig. 7). The interosseous muscle is then transferred to the adjoining digit to give abduction.

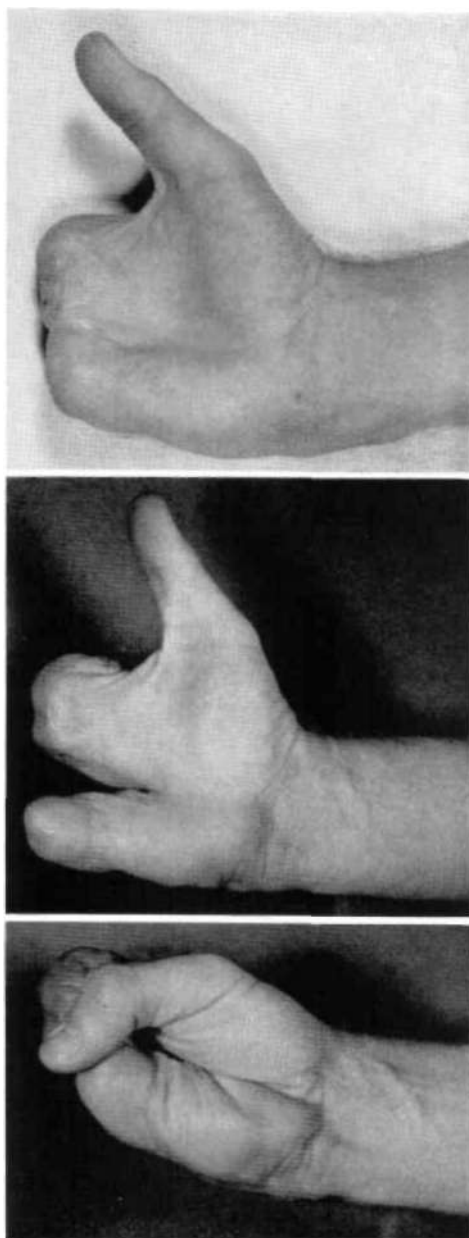
A hand amputated through all metacarpophalangeal joints or proximal phalanges may

be improved by mobilizing the fifth metacarpal, cutting the transverse metacarpal ligament, and perhaps removing the metacarpal of the ring finger and covering the cleft by a plastic maneuver (Fig. 4). The ulnar side of the hand thus becomes a movable

Fig. 4. Case M. S. Fingers lost between a sprocket and chain. Excised the tender neuromata of the stumps. Undermined and drew skin down for better coverage. Excised metacarpal of ring finger, covering sides of new digit by plastic maneuvers, in order to give more mobility (2 in.) to the metacarpal of the little finger. Deepened thumb cleft by Z-plasty (Fig. 21, page 86). The patient obtained a strong and useful grasp between the thumb, the phalangized index and long "fingers," and the little "finger." From Bunnell, *Surgery of the Hand*, 3rd ed., Lippincott, Philadelphia, 1956, by permission.

part. Motion may be increased as much as 2 in. If the second and fourth metacarpals are deleted, there will remain three digits, consisting of the metacarpals of the thumb and of the long and little fingers, and the thumb cleft will be wide and deep. Phalangizing the metacarpals gives considerable useful mobility so that one can dress oneself, use knife and fork, and so forth. The metacarpals of the thumb and little finger are cut across at the base and bent toward each other for better grasp (Fig. 8). A similar osteotomy may be performed on a hand having only two remaining digits, as for example thumb and little finger (Fig. 9), or even when only one complete digit remains, as in Figure 10.

Frequently a finger or hand stump is so hypersensitive from poor terminal padding and sensitive neuromata that it prevents all of the remaining parts of the hand from functioning. Crushing injuries to fingers present the most difficulty because, in such cases, the fingers usually have been damaged well proximal to the site of amputation. In revising such stumps, the digits must often be shortened enough to give good, well-padded cover, but it is possible to swing a visor flap from the dorsum over the end of the stump and then to skin-graft the dorsum. Still another possibility of furnishing good tactile cover over the end involves use of a cross-finger flap and then skin-grafting the back of the donor finger. Nerves in hands and fingers have a special tendency to proliferate. If they terminate in scar tissue or close under the skin, the neuromata formed may be extremely sensitive and give, on slight tapping, the sensation of an electric shock. These are corrected by uncovering the nerve, dissecting it well back, and cutting it off in



good tissue free from scar. Neither alcohol injection nor ligation is used.

#### STIFFENING IN THE POSITION OF NONFUNCTION

Following injury, infection, or paralysis, a hand frequently stiffens in the position of non-

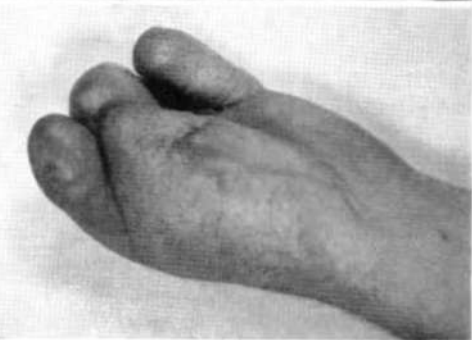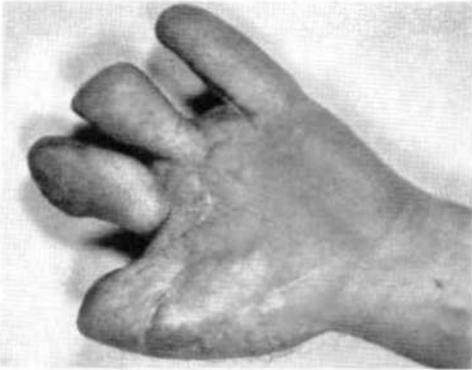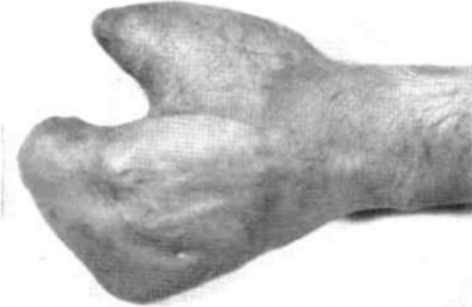


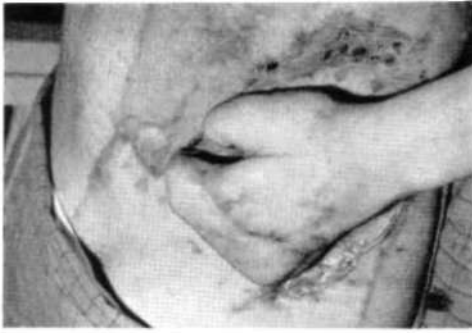Fig. 5. Case P. L. Hand caught between two rollers. Debrided and skin-grafted. Later, pedicle flap applied, then interdigitation. Sensation gradually returned throughout. A useful hand was obtained. From Bunnell, *Surgery of the Hand*, 3rd ed., Lippincott, Philadelphia, 1956, by permission.

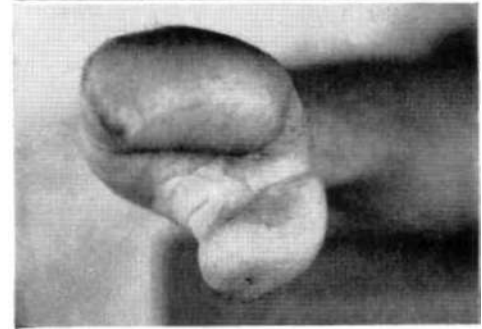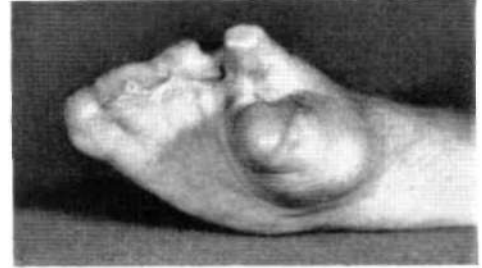

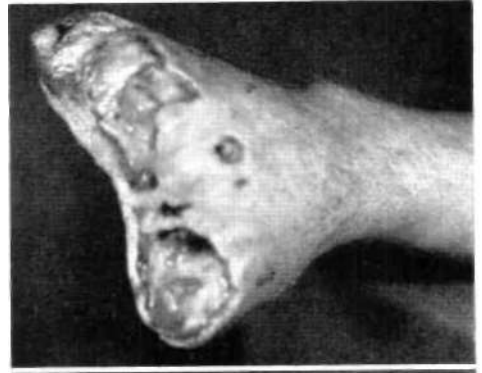
Fig. 6. Case B. P. Partial amputation by power saw. Split-grafted next day. Pedicle graft applied and thumb cleft deepened. Index metacarpal removed for wider cleft. Rotary osteotomy done on all metacarpals for better apposition. Pinning with Kirschner wires. A good "hand," with good prehension, was obtained. From Bunnell, *Surgery of the Hand*, 3rd ed., Lippincott, Philadelphia, 1956, by permission.

function so that the digits can no longer touch each other and the hand is therefore useless. In the position of function (Fig. 11), the wrist is extended 35 cleg., the joints of the fingers are moderately flexed, and the thumb is in moderate apposition, as in holding a baseball. In the position of nonfunction (Fig. 12), the wrist is flexed, the metacarpophalangeal joints are hyperextended, the remaining finger joints are flexed, and the thumb is at the side of the hand or even back of it. Al-

though such a hand is totally useless, in general it should not be amputated. For if the joints can be pushed around into the position of function, the available motion will be useful for picking up and holding objects, and the hand will be used more and more from then on.

The first approach to hands stiffened in the position of non-function involves use of a system of elastic or spring splinting by which joints can gradually be drawn around into positions of function. Usually the joints are kept active and are not damaged, and the muscles and all tissues are activated, a matter which greatly improves their condition. If, however, the response to such treatment is unsatisfactory, surgical means are resorted to, starting with capsulectomies (Fig. 13) and,



Fig. 7. Typical example of loss of fourth and fifth rays through the shafts of the metacarpals. In such a case, it is best to delete the stub of the fifth metacarpal and round the stub of the fourth. A corresponding procedure is advisable in the event of loss of the second digit, or of the second and third digits, by transmetacarpal amputation.

where there is damage to bone structure, resorting to arthroplasties.

Capsulectomies are usually performed on the metacarpophalangeal joints but sometimes also on the proximal interphalangeal joints. Usually the trouble is found to lie in the fact that the two collateral ligaments are too short and thick to permit the joint to flex. Excision of these structures makes flexion possible. Often it is necessary also to free the long extensor tendons (Fig. 14) and to clean out the volar pouch of the joint. In performing an arthroplasty, the metacarpal head is shortened and reshaped, and a hood of fascia is fastened over it.

Arthroplasty is not often done on the wrist joint; arthrodesis is used instead. In many cases, however, removal of a mass of scar tissue from the volar aspect of the wrist allows the wrist to extend. When pronation and supination are retained, arthrodesis of the wrist or of the proximal finger joints into the position of function gives very little disability (Fig. 15).

#### FLEXION CONTRACTURES AND FURNISHING NEW COVER

Most reconstruction commences with excision of a big plaque of scar tissue that is

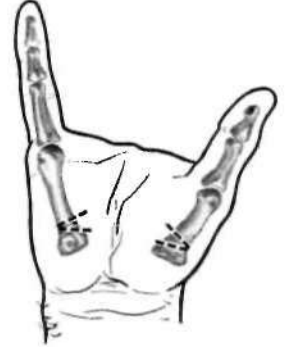

Fig. 9. Angulatory osteotomy of first and fifth metacarpals to aid apposition of thumb and little finger. Sometimes it is necessary to effect a tendon T transfer also. See Figure 31, page 91.

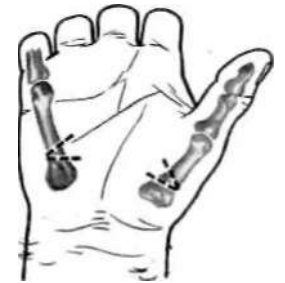

Fig. 10. Angulatory osteotomy of first and fifth metacarpals to bring thumb and ulnar side of palm into easy apposition. Tendon T transfer may be needed here also (Fig. 31, page 91).

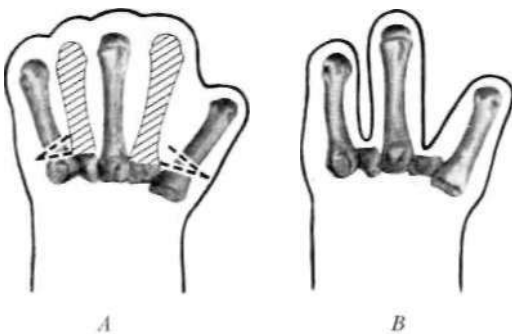


Fig. 8. Reconstruction procedure for loss of all digits through the metacarpophalangeal joints. A, Second and fourth metacarpals are deleted, clefts are covered by plastic maneuver, first and fifth metacarpals are osteotomized. B, Functional three-finger "hand" results

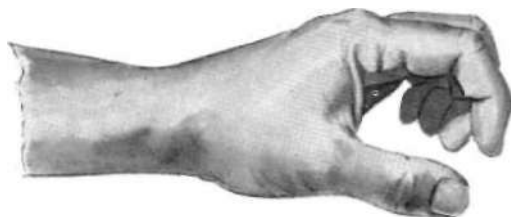

Fig. 11. The position of function.



Fig. 12. The position of nonfunction.

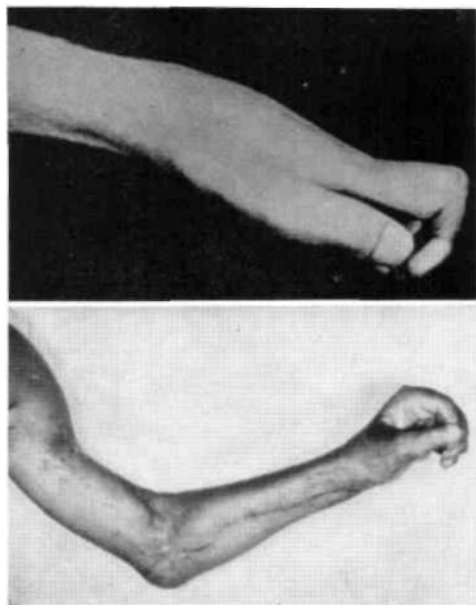


Fig. 13. Case E. T. Top, preoperative position of nonfunction from shark bite on upper arm, severing nerves and vessels. Bottom, correction to a position of function by fusion of the wrist, capsulectomies and opening of the cleft of the thumb, and transfer of the extensors of the wrist to the flexors of the fingers. A tendon transfer through a pulley constructed at the pisiform was used to give apposition to the thumb. No prosthesis needed. From Bunnell, *Surgery of the Hand*, 3rd ed., Lippincott, Philadelphia, 1956, by permission.

drawing the hand into flexion contracture and strangling the rest of the tissue (Figs. 16 and 17). The skin is then undermined and allowed to retract, thus freeing the hand for better nutrition. New cover is then provided, sometimes by a free graft but usually by a pedicle graft from the abdomen (Fig. 18), thus giving good, pliable skin with a layer of soft fat beneath. Doing so releases the whole hand and makes it possible to reconstruct the deeper parts—joints, bones, tendons, and nerves. Although the refinements of stereognosis never return to such skin, eventually sensation to light touch and pin prick develops.

#### SKELETAL MALALIGNMENT

The bones of the hand constitute the framework along which the muscles and tendons function in their proper planes. The joints allow the digits to flex and extend in their proper positions for adequate grasp. After fracture, bones often unite at such odd angles that the whole mechanics are thrown out of true. If, after healing, there is an angle of the bones along the length of the limb, the tendons over the convexity will be tight, over the concavity loose. Such a circumstance upsets the whole nicely adjusted muscle balance so that the joints are pulled into deformity all the way from the site of angulation to the end of the limb. To make the hand function properly again, realignment is necessary. The bones are chiseled or sawed across, a wedge being removed when necessary to place them in proper contact and alignment. They are then pinned so by Kirschner wires, the latter being withdrawn in two months when union is solid and the framework of the hand is restored.

When the thumb does not entirely contact the ring finger or the little finger, the metacarpal of either or both may be severed at the base and the digits angulated toward each other in such a way as to provide for easy contact. Similarly, in the absence of a thumb, two or more fingers may be angulated and rotated to give them the ability to work against each other.

When a metacarpal, including the soft tissues about it (tendons, nerves, interosseous muscles, and skin), is badly damaged, it may be excised. If it is one of the central rays, the

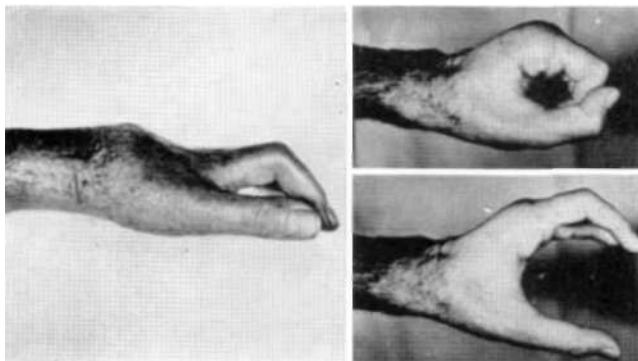


Fig. 14. Case J. D. Left, old dislocation of metacarpals on carpus, upsetting muscle balance, thus resulting in the useless position of nonfunction. Right, dislocation reduced, restoring muscle balance in the position of function. A pedicle graft was applied to the dorsum of the hand and to the open thumb cleft. Freeing of the extensor tendons, together with capsulectomies, allowed the proximal finger joints to flex. No prosthesis needed. From Bunnell, *Surgery of the Hand*, 3rd ed., Lippincott, Philadelphia, 1956, by permission

metacarpal of the adjoining ray, either index or little, as the case may be, is cut across at its base, jogged over to the base of the excised metacarpal, and pinned near and parallel to the next ray (Fig. 19).

When a metacarpal head is missing, the lack of support causes the adjoining metacarpals to rotate so that the fingers cross on flexion. In such a case, the metacarpal can be excised and one of the adjacent ones jogged over. Or the proximal phalanx of the ray in question can be recessed, or set back, so that its head will take the place of the missing metacarpal head.

Often it is advisable to arthrodese a joint to place it rigidly in the position of function. This procedure can be carried out on either of the two distal joints of the fingers but rarely on

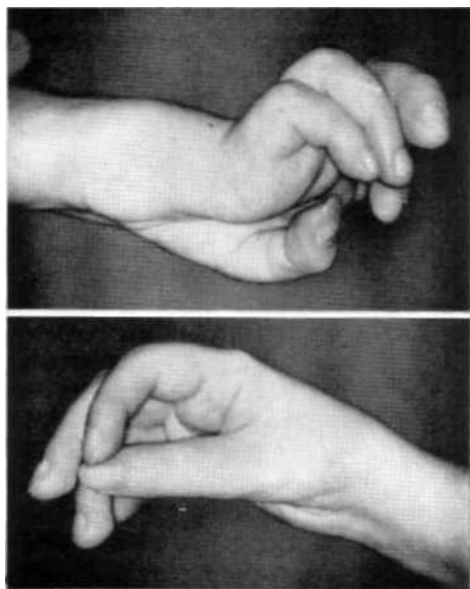
Fig 15 Case A B Hand useless from birth pals)". Several operations had been performed, including fusion of the wrist. The proximal finger joints were lax and bent backward out of use. Patient could not abduct at the shoulder, and the forearm was in supination. The shoulder was arthrodese to enable placement of the hand, and by osteotomy the ulna was rotated into pronation. The proximal finger joints were arthrodese into the position of function. Patient gained much use of the hand and became self-supporting. From Bunnell, *Surgery of the Hand*, 3rd ed, Lippincott, Philadelphia, 1956, by permission.

the proximal joints. It is done on the wrist and can be done on the elbow. In the latter case, the choice must be made between arthrodese, a block operation, muscle transfers, or the wearing of a prosthesis to activate a flail elbow. When the arm cannot be abducted at the shoulder but when muscles around the scapula are good, arthrodese of the shoulder will allow the arm to position the hand for useful function (Fig. 20).

#### THUMB PROBLEMS

So essential to prehension is the thumb that every possible bit of an injured one should be saved. Amputation of the thumb through the metacarpophalangeal joint results

in a partial digit almost too short to be useful, but a new thumb cleft can easily be made by a Z-plasty operation (Fig. 21), meanwhile scraping the adductor origin down from the third metacarpal. The thumb is thus made relatively longer. If the shaft of the index metacarpal





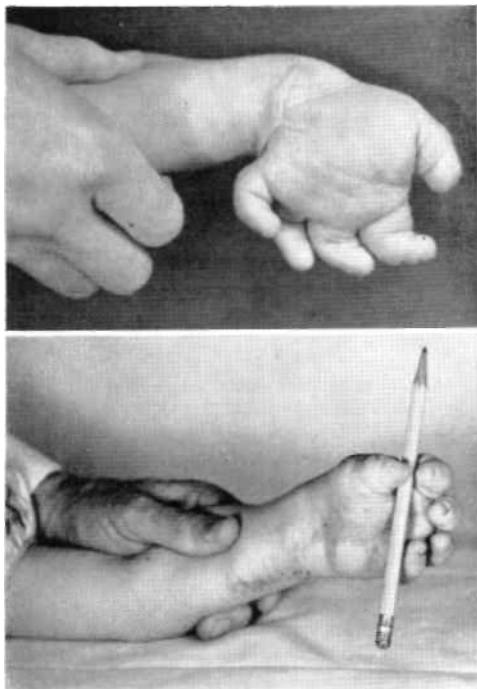


Fig. 16. Case J. M. From birth the cicatrix from a tear at the ulnar side of the wrist so distorted the growth of the hand that there was no function. The scar was excised, the ulna elongated, and a pedicle applied. Two years later osteotomies were done on all metacarpals, the thumb cleft was deepened, and a pulley operation was performed to improve apposition. Three years later the hand was reported to be quite useful. From Bunnell, *Surgery of the Hand*, 3rd ed Lippincott, Philadelphia, 1956, by permission.

back of the hand, with the nail at right angles to the palm, through a wide ellipse toward the volar aspect until it is opposite the fingers, the nail being then parallel to the palm. In the latter position, the thumb is available to participate with the fingers in grasping large objects. The motion is effected by the ten muscles—long and short—that control the thumb. In paralysis of the median nerve, in injury to the thenar muscles, in stiffness of the carpometacarpal joint of the thumb, or in flexion contracture on the dorsum of the web,

projects into the web so as to interfere with grasping, it should be excised at its base to widen and deepen the cleft (Figs. 22 and 23). Whenever possible, the tip of the third metacarpal should be preserved to provide a concave palm for the remnant of the thumb to work against (Fig. 22). Preservation of the broad tip of the third metacarpal is particularly desirable when a complete thumb remains (Fig. 24).

The range of motion of a normal thumb extends from a position at the side and slightly

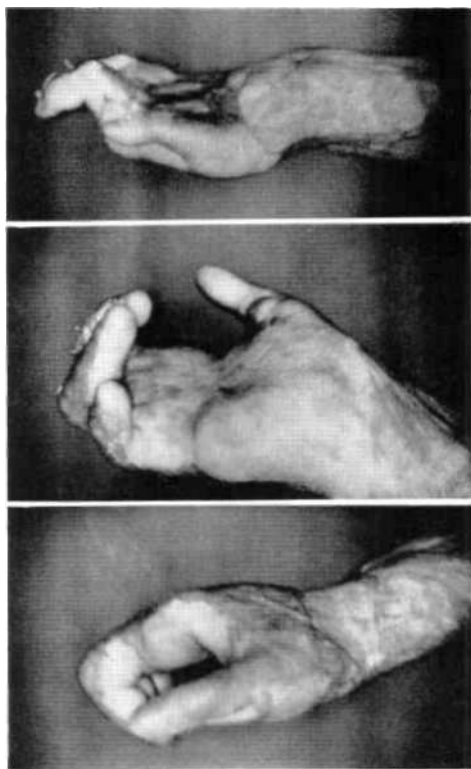
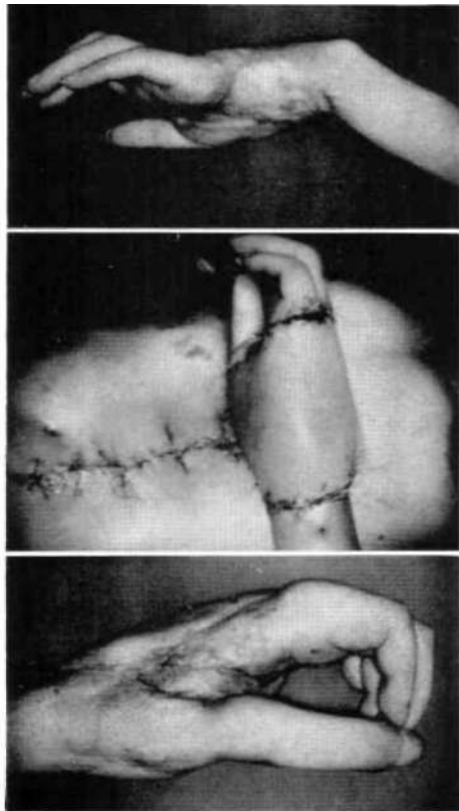


Fig. 17. Case D C. M. Hand severely burned in oil fire so that all digits pointed backward out of use. Fingers were webbed, and middle joints were exposed. There was no thumb cleft, the thumb being at the rear of the hand with the metacarpal arch reversed. In this position of nonfunction, the hand was entirely useless. Excised all dorsal skin, including nails. Sawed away exposed bone. Corrected webs. Established thumb cleft and positioned thumb. Positioned fingers by capsulectomies. Covered all with free skin graft. Patient returned to his job as locomotive engineer. No prosthesis needed. From Bunnell, *Surgery of the Hand*, 3rd ed., Lippincott, Philadelphia. 1956, by permission.

## NONFUNCTIONAL HANDS

Fig. 18. Case A. C. Hand badly crushed between rollers. Poor skin surface, position of nonfunction, entire hand and joints stiff, extensor tendons adherent, thumb at side, amputation contemplated. First operation: excised all skin from both dorsal and volar surfaces, covered with one large pedicle graft, and spread thumb from hand; brought joints around by elastic splints. Second operation: freed extensor tendons and placed fat beneath; did capsulectomies on proximal joints; used sublimis of long finger for apposition; freed flexor tendons, placing fat beneath; defatted pedicle. The hand made remarkable recovery in nourishment, function, and position. There was good grasping power and a complete change in the morale of the patient. No prosthesis needed. From Bunnell, *Surgery of the Hand*, 3rd ed, Lippincott, Philadelphia, 1956, by permission.



normal range of motion of the thumb is lost. If the other parts of the hand are mobile, the ability to appose the thumb can readily be provided by a simple tendon transfer that draws the thumb toward the pisiform bone and pronates it. When this is not possible, the thumb may be held permanently in a useful position by a bone graft at the base of the first metacarpal.

When a thumb is closely bound to the rest of the hand by scar, it can be spread away by excising the scar tissue and cutting across the cleft from a point opposite the hinge of the first two metacarpals on the dorsal side to the corresponding point on the volar side. The thumb is spread to the side and front of the hand, and the large denudation of skin is covered either by a large diamond-shaped free skin graft or, better, by a pedicle graft from the abdomen. In three weeks, pedicle grafts are detached from the abdomen and laid smoothly on the hand.

Although the thumb stump remaining after amputation through the metacarpophalangeal joint usually is not very serviceable, it may be built out by pedicle and bone graft. If a thumb is amputated proximal to the metacarpophalangeal joint, it should in any case be built out longer. If the thenar muscles and the stub of

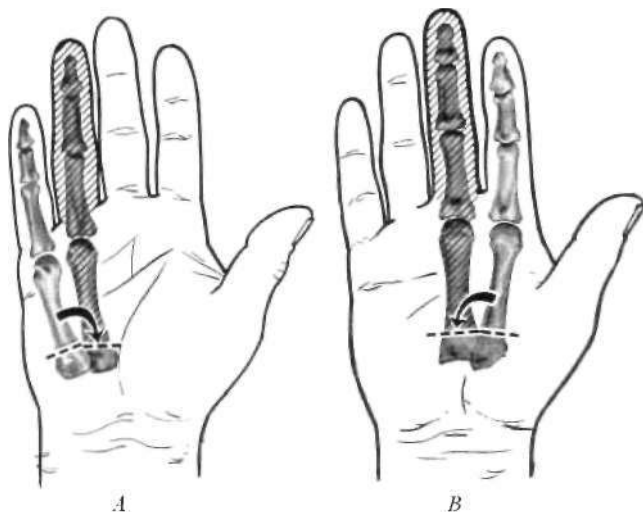


Fig. 19. Reconstruction procedure recommended in event of serious damage to (A) the fourth digit or to (B) the third digit. In A, delete the much-injured fourth ray and jog fifth ray over to its place. In B, delete the much-injured third ray and jog second ray over to its place. The result in either case is a functional four-digit hand.




Fig 20. Case L. M. W. As a result of polio, arm was flail at shoulder, and there were no flexors in the hand. Arthrodesed shoulder and wrist simultaneously so that the patient could place the hand. Transferred extensor carpi radialis to flex fingers, palmaris longus to abduct thumb, the long extensor of the ring finger for apposition. Slit the proximal pulleys so that long flexors could flex the proximal joints. Patient gained much use of hand, was able to grasp a piece of paper or a tumbler, could place the hand well, and occupied a position in a bank. No prosthesis needed. From Bunnell, *Surgery of the Hand*, 3rd ed., Lippincott, Philadelphia, 1956, by permission.

the metacarpal remain intact, the thumb will be quite movable. A short thumb is a good thumb. Various motions, such as apposition, extension, and flexion, may be furnished it by tendon grafts.

In the case of total loss of the thumb, a new one can be supplied in various ways. The simplest approach is to raise a tube pedicle from the abdomen, attach the pedicle to the hand, and place in it a bone graft from the iliac crest (Figs. 25 and 26). Although this expedient gives sensation, it does not provide much stereognosis. Nevertheless, a reconstructed thumb is apt to be very serviceable and considerably better than a prosthesis.

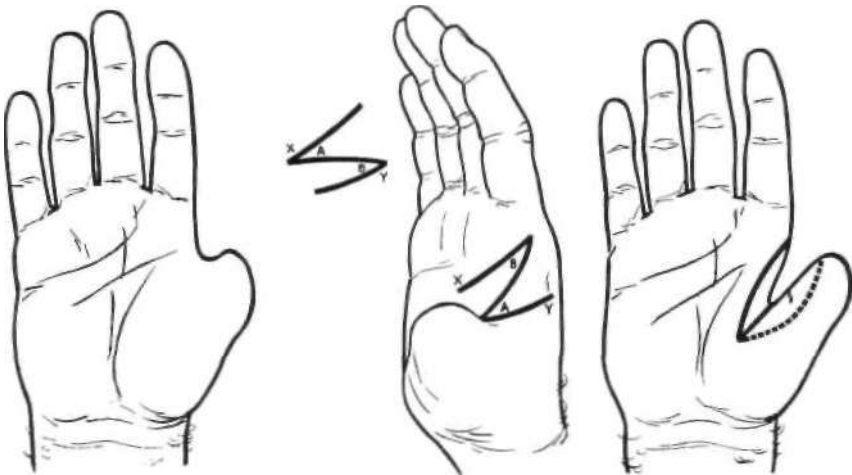


Fig. 21. Phalangization of thumb cleft by Z-plasty. Left, hand with short and more or less useless thumb stump. Middle, location of Z-shaped incision; flap A is carried to fixed point X, flap B to fixed point Y, so that dorsal flap just covers defect on volar side while volar flap just covers defect on dorsal side; resulting suture line is as shown in insert. Right, end-result, showing deepened thumb cleft.

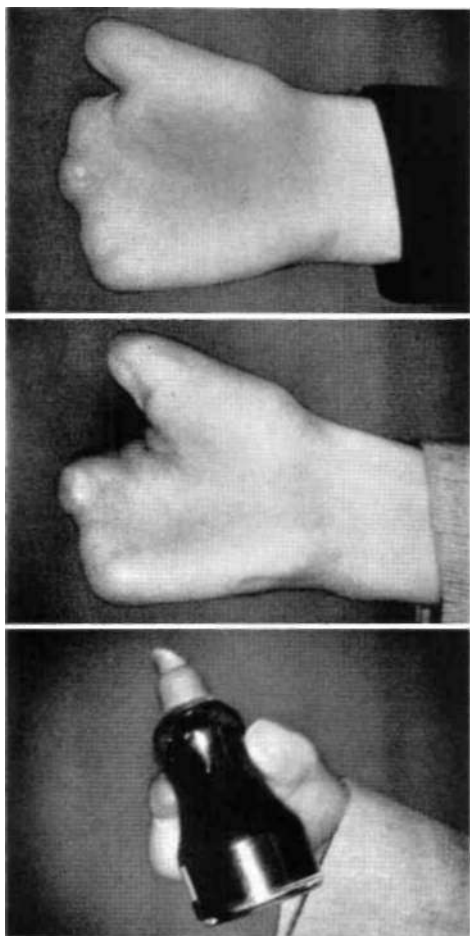


Fig. 22. Case C, H. Amputation by meat grinder. Thumb cleft deepened by Z-plasty. Index metacarpal removed to give good grasp. From Bunnell, *Surgery of the Hand*, 3rd ed.. Lippincott, Philadelphia, 1956, by permission.

The graft should be grounded on some other bone rather than connected by a joint. It may be placed on the carpus to make a pad in the base of the palm, or it may be placed on the trapezium or on the stub of the metacarpal.

The requirements of a new thumb are three in number—motion, sensation, and proper placement. The best new thumbs are made by pollicization of a finger, preferably the index finger but sometimes the long finger. Often, as part of the injury, the index finger is already somewhat shortened. In such a case, the

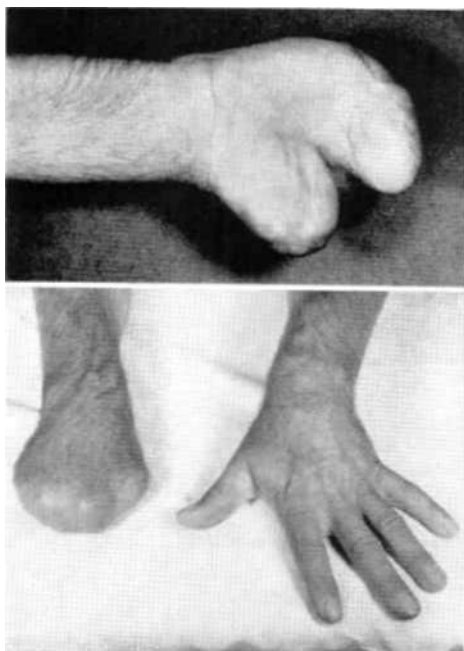


Fig. 23. Case H. G. Amputation, by power saw, of all digits through proximal phalanges, leaving a mitten hand but no thumb cleft. By a plastic maneuver and removal of the index metacarpal, a thumb cleft  $\frac{3}{4}$  in. deep was constructed. It opened  $\frac{3}{4}$  in. and closed against the hand. Patient could write and hold objects. Limited facility can be combined with the use of a prosthesis. From Bunnell, *Surgery of the Hand*, 3rd ed., Lippincott, Philadelphia, 1956, by permission.

linger, or a portion of suitable length, is transferred together with a bridge of skin and with its nerves, blood vessels, and tendons intact (Figs. 27 and 28). It may even be transferred on a neurovascular pedicle circumscribing the skin all around (Fig. 29). When this

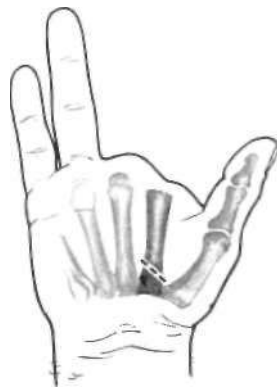

Fig. 24. Operative procedure for loss of the second and third digits. Excision of the second metacarpal, but with retention of the third, furnishes easy apposition for the sound thumb.

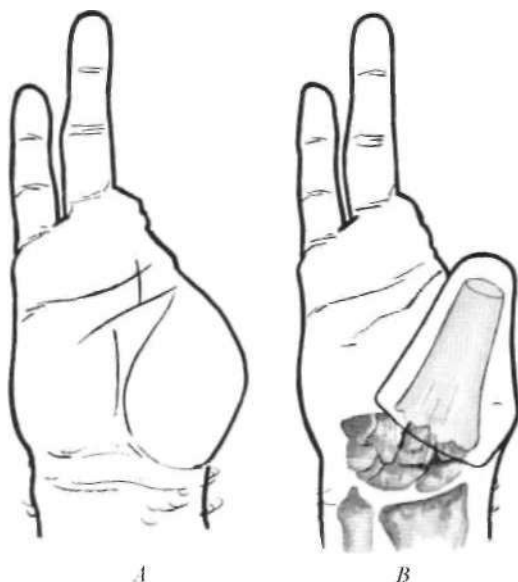


Fig. 25. Surgical construction of a new "thumb." A, Poorly functioning partial hand retaining digits four and five only. B, Serviceable partial hand made by constructing new "thumb" with pedicle and bone graft. Function is apt to be better than if a prosthesis were applied.

procedure is possible, it makes for easy and exact placement. The tendons are brought over with the new "thumb" and joined up so as to give motion. The fingers should work directly against the new "thumb" and also, by their side motion, should pass to the side of it and close against the palm. Stereognosis and vascularization are provided by the neurovascular pedicle.

Should a newly constructed thumb not have sensation in its tactile area, a flap of skin may be exchanged for the nontactile skin by a Z-plasty. Or tactile skin can be furnished by using a neurovascular pedicle passed beneath the skin at the base of the thumb. A living thumb, with motion, sensation, and proper positioning, is, of course, far superior to any prosthetic thumb.

#### TENDON REPAIR

Tendons are frequently lacerated, thus losing their function of transmitting muscle power to provide motion in joints. They can, however, readily be repaired (Fig. 30), the most difficult cases being the flexor tendons in

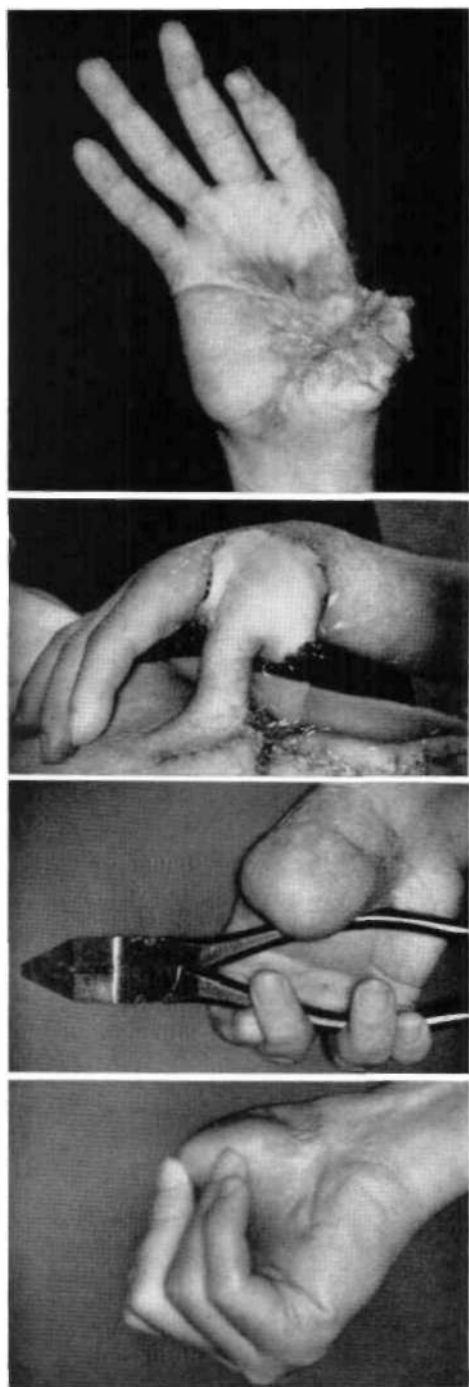


Fig. 26. Case C. B. Injury from hand grenade. Pedicle graft covered the thumb, and arthrodesis was done on the trapezium by a graft from the ilium. Abduction was furnished index finger by a proprius-tendon graft. A very useful hand resulted. No prosthesis needed. From Bunnell, *Surgery of the Hand*, 3rd ed., Lippincott, Philadelphia, 1956, by permission.

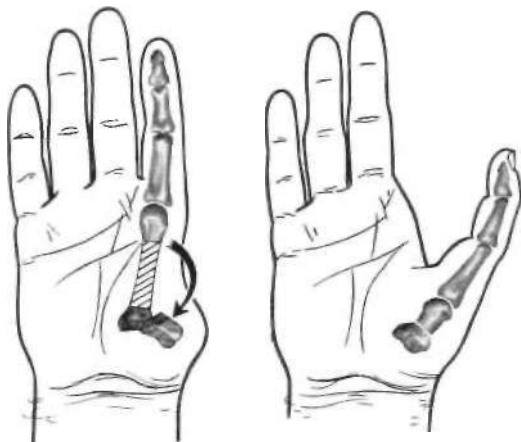


Fig. 27. Pollicization of index finger,

the digits and in the distal part of the palm, where the resulting juncture tends to adhere to the surrounding parts. Frequently a tendon graft must be used to bridge the tendon over areas where adhesions are likely to form. Adherent tendons may be freed, and slippery material, such as paratenon and fascia, may be grafted between them and the bones so as

to allow the tendons to glide again. Defects in tendons are readily bridged by free tendon grafts from spare tendons in other parts.

The upper limb interdigitates at the ends of the metacarpals, and the tendons normally have individual motion. If either an extensor or a flexor tendon is sutured over a finger stump, it will hold back all of the tendons pulled from the same muscle. But when all of the tendons are cut at the end of a carpal or metacarpal stump, they should all be sutured together over the end to provide for movement of the stump.

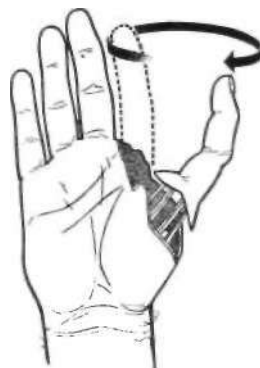

Fig. 29. Pollicization of index finger by neurovascular pedicle. Skin is circumscribed, and the index finger is pinned on to the stub of the metacarpal of the thumb in proper position. Tendons furnish motion, vessels nutrition, and nerves sensation.

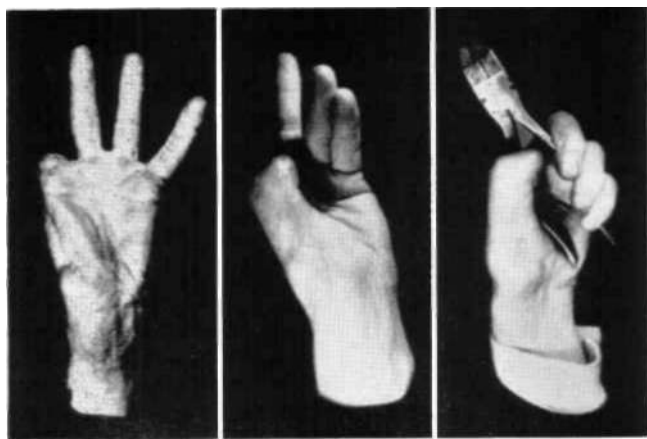


Fig. 28. Case H. W. W. First (1929) physiological reconstruction of thumb by pollicizing remains of the index finger. Metacarpal lashed to trapezium, nerves and vessels carried over, and all tendons and muscles connected up. "Thumb" had strong motion and normal sensation and was well positioned. Patient worked well as a carpenter for 20 years. Superior to prosthesis From *Surgery, Gynecology, and Obstetrics*, by permission.

Isolated digits may be made to provide prehension if they are furnished with new flexor and extensor tendons. To make the fingers appose each other, the tendons can be placed diagonally across the hand, or a tendon T transfer, which consists of one cross-bar tendon from digit to digit and a longitudinal one looped about the first, can be made (Fig. 31). When the muscle concerned is contracted, the "T" assumes the shape of a "Y," and the two digits are drawn toward each other. This procedure is particularly useful in median and ulnar paralysis, where it will provide adduction of the thumb and little finger while curving the metacarpal arch of the palm. When some digits have been amputated, great strength can be given to the remaining fingers by transferring in the forearm the

tendons of the amputated ones to those of the remaining ones.

Especially in paralysis are tendon transfers useful. Good, strong muscle and tendon are transferred to the tendons of the paralyzed muscles. This operation may be performed, without fusing the wrist, to give very good return of function so that splints are discarded. In the case of any two nerves paralyzed high in the arm, the wrist can first be arthrodesed in the position of function, an expedient which results in very little disability. Thereupon the five tendons previously wrist movers become available as digit movers, and the resulting motion is more natural than that obtained

using a prosthesis. The patient soon learns to adapt so that the motion becomes natural. A rule is to decide what movements are needed and then to consider the number of muscles available for transfer. For paralysis within the hand—that is, from the median and ulnar nerves—many transfers are available to restore muscle balance, thus correcting the position of the claw hand by substituting for the paralyzed intrinsic muscles.

Another principle is tenodesis, a procedure in which the tendons that move the digits are fastened to the forearm bones. Then, when the wrist is flexed, the extensor tendons tighten and extend the digits; when it is extended, the flexor tendons tighten and cause the digits to flex so that thumb and fingers appose each other. These automatic movements are useful when only one or two strong muscles are available. When no muscles are available, the hand can be converted to a useful hook by tenodesis of the flexor tendons to the forearm bones.

#### NERVES

Movement and sensation in the hand, which are its two most important functions and which are of equal value, depend entirely upon the nerves. The three large nerves that course down the arm (the ulnar nerve, the median nerve, and the radial nerve) control the hand, and any injury to them is as damaging to the hand as is an injury to the hand itself. When a nerve is severed, it should be

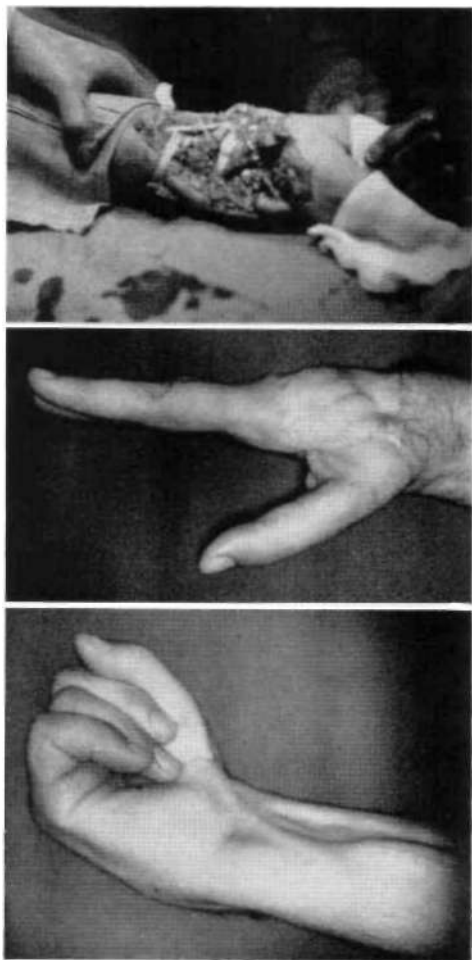


Fig. 30. Case F. E. Charge from a shotgun entered palm and emerged dorsally, shattering the carpus and the lower radius and severing many tendons, extensors of the wrist, thumb, and fingers, and the median nerve. Debrided, filetted the index finger, and skin-grafted. Considerable infection followed. First operation: excised scar and placed a pedicle. Second operation: furnished tendon grafts plus paratenon to extend thumb and fingers; freed the flexor tendon of the thumb; did a pulley operation for apposition; sutured median nerve to its four branches. The wrist became fused. But sensation, motion, and apposition returned, so that there resulted a very useful hand requiring no prosthesis. From Bunnell, *Surgery of the Hand*, 3rd ed. Lippincott, Philadelphia, 1956, by permission.

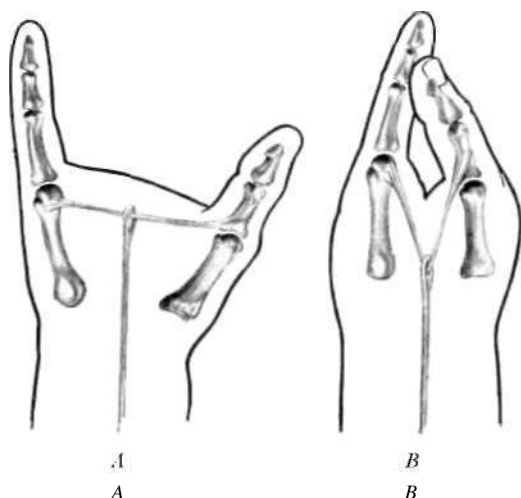


Fig. 31. Lobster hand formed by tendon T transfer. A, Arrangement of tendons to form the "T." B, Contraction of the longitudinal tendon converts the "T" to a "Y" and thus effects apposition of thumb and little finger.

rejoined at once. Otherwise fibrous degeneration in both the lower portion of the nerve and in the muscles supplied by it will be so progressive that, after two years, muscle action will not return and, after five years, neither will sensation. A gap of several inches can be overcome and the nerve sutured directly. Even the little nerves in the hand itself can be repaired.

After nerve suture, there is about 80 percent of functional recovery. Nerves can be sutured directly, transferred, or even free-grafted. All of these procedures are successful, but nerve grafts must be used from the same person; if

grafted from another person, they will melt away. From loss of nerve supply, the hand if neglected goes into the position of nonfunction, stiffens, and atrophies. Splinting should be by spring or elastic splints sufficient just to substitute for the paralyzed muscles and to hold the hand in the position of function so it can work. When the nerves are irreparable, as for example when too great an interval has elapsed since the time of injury, muscle function in the hand can be provided by tendon transfers. Paralysis in the hand and forearm from ischemic contracture can be overcome to a considerable degree, although never completely cured. In vasomotor disorders, surgery seldom need be weighed against prostheses.

#### PROSTHESES FOR PARTIAL HANDS

The literature on prostheses for the partial hand is meager, and therefore when a hand is damaged there is a distinct preference on the part of prosthetists to have a wrist disarticulation or a long-below-elbow amputation. In the event they are confronted with a partial hand amputation, many limbfitters prefer to enclose the wrist immobile (as in Figure 32) rather than to construct a partial hand prosthesis. Even those who furnish cosmetic-glove prostheses (as in Figure 33) prefer to enclose the whole hand in the glove and to substitute, for the missing parts, foam filler reinforced with pliable wire. Although a long-below-elbow amputation offers the advantage that many more or less standard terminal devices may be applied (a split hook, a mechanical hand, perhaps some special tools), a partial



Fig. 32. One form of prosthesis for partial hand amputation—thumb free, wrist encased, split hook activated by shoulder harness as in the case of the wrist disarticulation. The disadvantages are numerous. The long cuff virtually eliminates any possibility of wrist motion. Except in the thumb remnant, residual tactile sense is obviated, and the device as a whole is much too long.



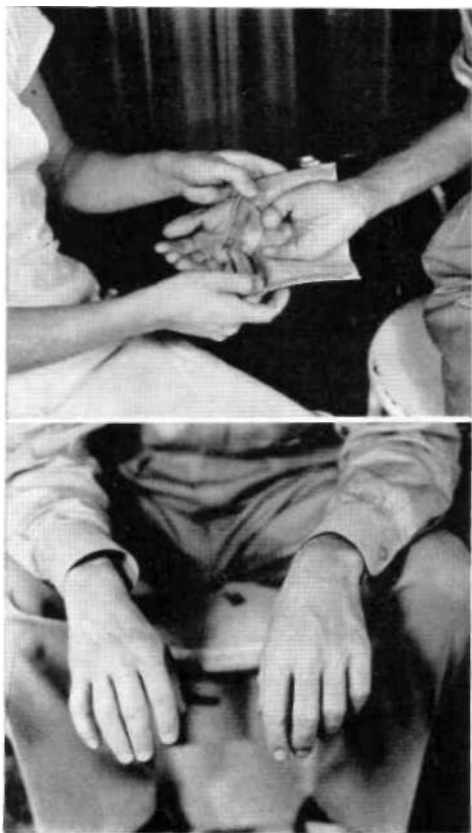


Fig. 33. Cosmetic hand for partial amputation—glovelike and zippered at the wrist. Fingers are filled out by foam filler and stiffened by armature flexible enough to hold any shape. *Courtesy Prosthetic Services of San Francisco.*

hand, whatever can be saved, can often be fitted with considerably more success. If the thumb alone is spared, a casing over the palm and wrist can support a pad or other suitable device against which the remaining digit can work (Fig. 34). If only the palm, perhaps with a few remnants of phalanges, remains, a casing over the forearm can support a similar pad against which the palm can be pressed by wrist flexion (Fig. 35).

By the combined talents of engineers, physicists, prosthetists, orthopedists, and others, there have been in the last ten years



Fig. 34. Simple prosthesis for loss of all digits except the thumb.

many advances in hand and arm prostheses. Accordingly, there has been developed the policy of saving as much of any limb as is likely to be functional and, particularly, as much of the hand as possible. Any portion of skin with sensation should be preserved because of the possibility of placing it in a functional part. Digits with sensation can do light work and, if necessary, a prosthesis can be applied to do heavy work (as in Figures 36 and 37).

For the wrist-disarticulation, below-elbow, above-elbow, and shoulder-disarticulation prostheses, many new devices have been developed. They include the alternator elbow lock for the above-elbow case (3,5), the outside-locking elbow hinge for elbow disarticulation (1,3,5), the polycentric elbow joint for below-elbow cases (1), the variable-ratio step-up hinge for the very short below-elbow case (1), the flexible cable units to allow pronation and supination for the very long below-elbow and wrist-disarticulation cases (8), and the elbow-coupled shoulder joint for shoulder-disarticulation amputees (7). For the arm amputee, these devices help to carry the terminal device (hook or artificial hand) to a place of usefulness. The *Manual of Upper*

*Extremity Prosthetics* (11) gives a full account of these and other devices that comprise a full armamentarium for upper-extremity amputees. But the case of the partial hand amputation is not included.

#### PROSTHESES FOR ONE-DIGIT HANDS

For most practical purposes, loss of one or more distal phalanges does not require application of a prosthesis. Nevertheless, there are exceptions. An accomplished violinist, losing the distal phalanx of even one string finger, for example, is incapable of managing the strings properly. This could mean an occupational change for such a person. A good prosthetic replacement may enable him to continue his occupation. The same occasionally occurs with an organist, a pianist, a typist, or other person in any occupation where finger dexterity means the difference between success and failure. A suitable prosthesis for such a case can be made using thin stainless steel for the socket and extension framework and then dipping the device in flexible vinyl plastic to form the tip cushion and finger build-up. The socket portion may be split along one side to allow it to expand and contract, thus ensuring snugness of fit.

For amputation of all of the fingers at the metacarpophalangeal joint, or approximately half an inch distal thereto such that the volar crease of the metacarpophalangeal joint remains, a 1/8-in. rod framework of stainless steel can simulate the socket while leaving a maximum amount of exposed palm for traction and sensation (Fig. 38). The distal portion of

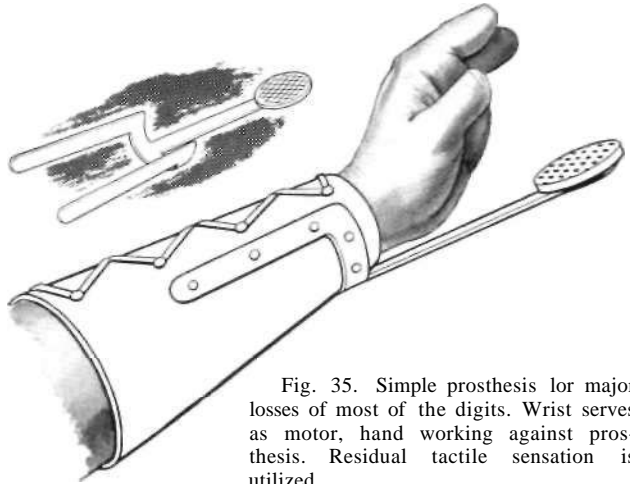


Fig. 35. Simple prosthesis for major losses of most of the digits. Wrist serves as motor, hand working against prosthesis. Residual tactile sensation is utilized.

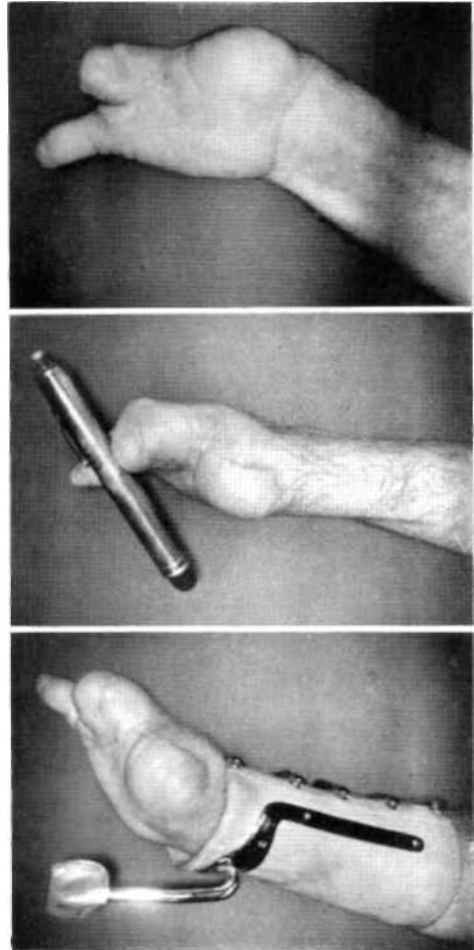


Fig. 36. Partial hand capable of prehension. Top and middle, digital motion for light work. Bottom, wrist motor for heavy work. From Bunnell, *Surgery of the Hand*, 3rd ed., Lippincott, Philadelphia, 1956, by permission.

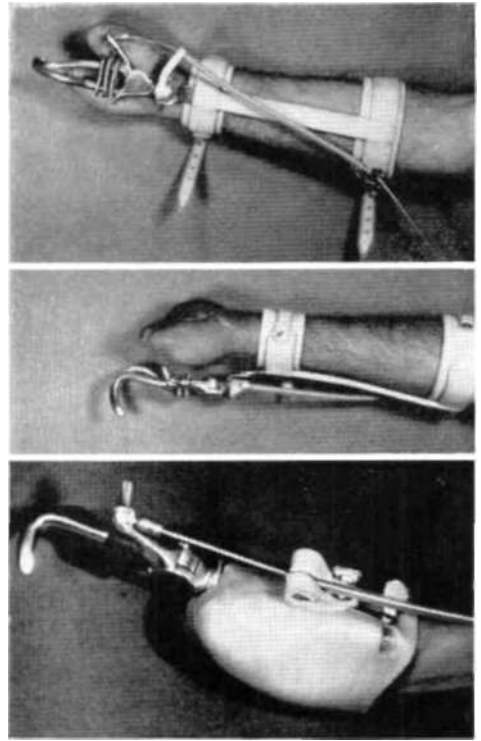
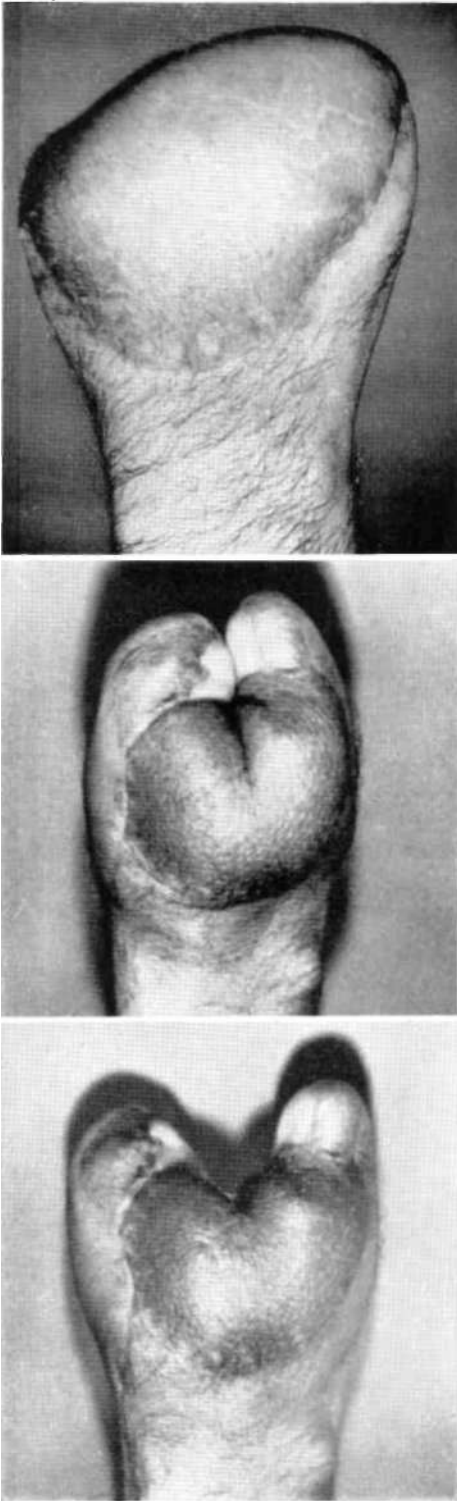


Fig 37. Case E. E. Left, top to bottom: Right hand pulled into hay chopper. Debridement and abdominal pedicle. Later a two-digit hand was made with a tendon T operation for prehension and a spread of 1-1/2 in. Right, top and middle: A prosthesis which enabled the hand to work against a hook. This was discarded because it was too unstable. Right, bottom: A prosthesis made by Robin-Aids Manufacturing Company, Vallejo, Calif., that was very satisfactory. It preserved residual wrist motion and could be removed when fine digital motions were required.

the framework is bent to simulate the finger tips, the little-finger side being curved to form a hook for pulling or lifting and the index side shaped to appose the thumb as would the first two fingers in three-jaw-chuck prehension (4). This arrangement provides for prehension between the simulated index finger and the remaining thumb. A similar appliance can be made for an amputation proximal to the metacarpophalangeal joint, but in such a case the remainder of the hand must be fitted with a plastic, metal, or leather socket for attachment to the formed rod (Fig. 39). The notable

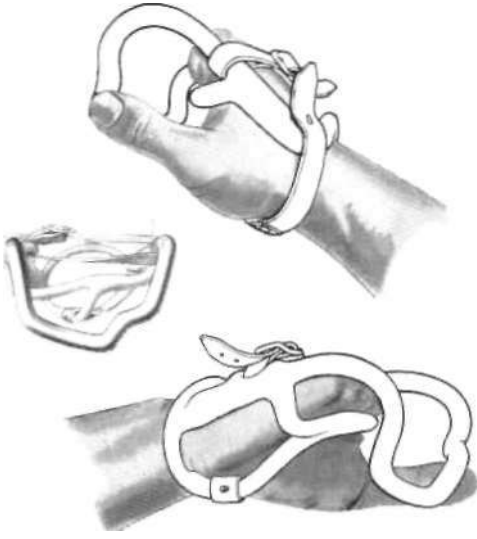


Fig. 38. Prosthesis for loss of all the fingers at, or slightly distal to, the metacarpophalangeal joint line. Metal ring, covered with vinyl plastic, is so shaped as to furnish one large hook, representing the index finger, and one small one, representing the little finger. Thumb works against ring throughout the range of the carpo-metacarpal articulation. *Courtesy Robin-Aids Manufacturing Company, Vallejo, Calif*

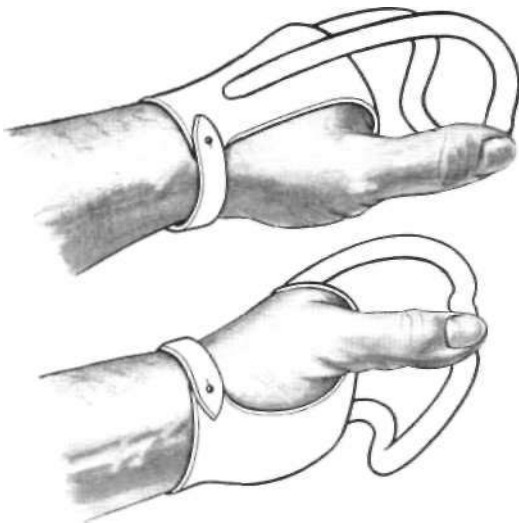


Fig. 39. Prosthesis for transmetacarpal amputation. Socket may be of leather, molded plastic, or hammered stainless steel. Metal ring, covered with vinyl plastic, is shaped to simulate fingers, as in Figure 38. *Courtesy Robin-Aids Manufacturing Company, Vallejo, Calif.*

disadvantage is the coverage of surfaces otherwise capable of sensation. In both instances, the rod framework is dipped in flexible vinyl plastic to provide a surface with adequate traction.

Figure 40 shows a single stainless rod curved in hook fashion and mounted to a stainless-steel plate, which in turn is attached to a molded hand and wrist socket. The hook is so positioned as to give apposition to the thumb, and the thumb is exposed to utilize its capability for sensation. This single hook, being small and smooth, allows easy entry into pockets and other tight places.

Since the thumb is the most important single digit of the hand, it would seem a sound principle not to involve it as a motor for powering other mechanisms. A collar around the thumb would appear to diminish tactile surface, and any mechanical linkage would seem to lessen mobility and dexterity. In general, wrist flexion-extension provides a far more desirable motor with less hindrance to function. But these principles have only general applicability and are not specific. For certain special needs, a thumb-powered mechanism may be desirable. In any individual case, the selection of equipment must be left to the mutual judgment of the patient, the doctor, and the prosthetist. Figures 41 and 42 illustrate the principles involved but show the distinct differences to be found in individual cases.

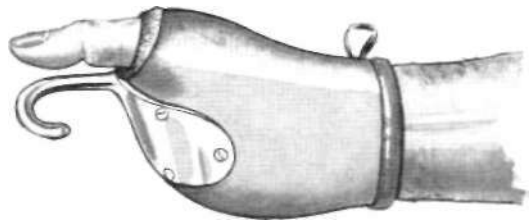


Fig 40 Simple prosthesis for loss of most of the palm but with retention of the thumb. Wrist and hand stump are encased in a socket to which is attached a single stainless-steel hook. The hook may be used by itself or as a member for apposing the thumb.

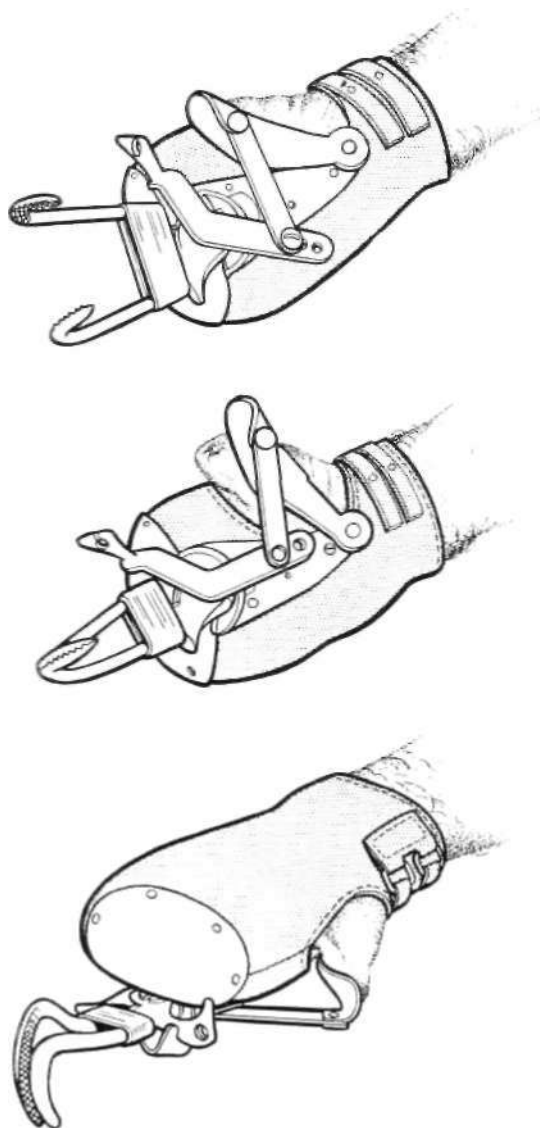


Fig 41. Prosthesis for amputation of all fingers at the metacarpophalangeal joint line with retention of the thumb. Socket about wrist and hand stump supports split hook, which is powered by the thumb. *Courtesy Navy Prosthetics Research Laboratory, U.S. Naval Hospital, Oakland, Calif.*

In the arrangement shown in Figure 43, the hand, wrist, and forearm socket give versatility for the accomplishment of either light tasks or

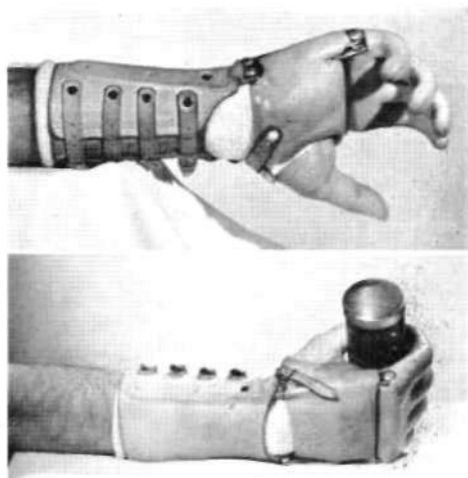


Fig 42. Prosthesis for loss of all digits but the thumb. Hinged at and powered by the wrist, this device provides for prehension by virtue of a thrust rod. *Courtesy Robin-Aids Manufacturing Company, Vallejo, Calif.*

heavy-duty work. For light tasks, the thumb stump is free to appose the remainder of the hand or to contact a small metal post or spoon attached to the hook. The forearm socket allows freedom of wrist motion but provides hook stability for heavy-duty work. Since the thumb stump is also free to appose the hook-activating lever, no shoulder harness is required.

For a hand retaining only the thumb, without fingers or even without their metacarpals, a special prosthesis designed by the United States Navy gives reciprocal motion and active prehension powered by the thumb (Fig. 44). To a simple hand cuff and wrist strap is attached a metal plate, which, on the radial side, supports a lever for the thumb to appose and, on the ulnar side, bears a metal finger pivoted on an axis near the base. Apposition of thumb and metal finger is effected by a linkage between the two lever systems.

#### PROSTHETIC THUMBS

Figures 45 and 46 illustrate fixed prostheses for partial or complete loss of the thumb. Two features are essential. First, the prosthetic

thumb must furnish proper apposition to the fingers, and its lip should be of such material as to provide adequate traction. Second, the thumb must provide a shaft and a crotch so as to make it possible to hold objects too

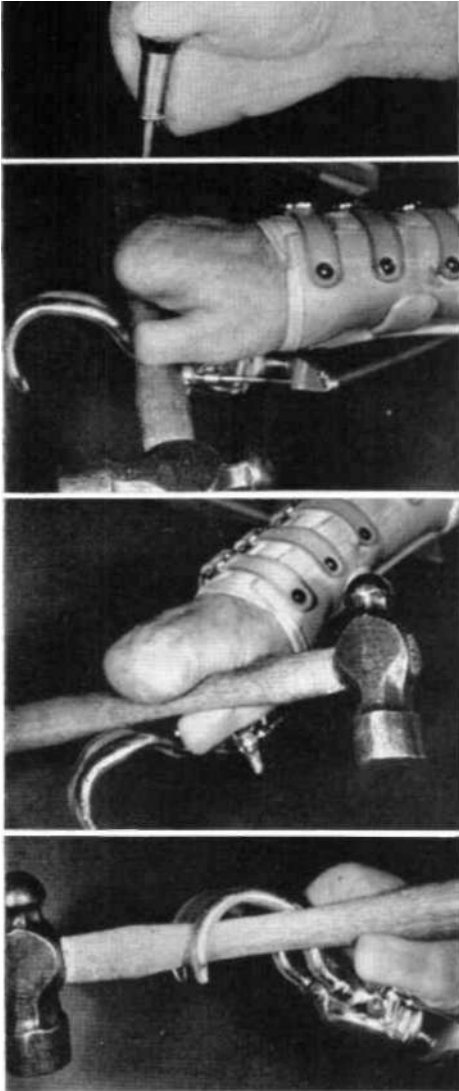


Fig. 43. Amputation of the fingers at the metacarpophalangeal joint line and of the thumb at the interphalangeal joint; thumb phalangeized for deeper cleft. Top to bottom: holding with thumb unassisted; use of hook (powered in this case by shoulder harness) as device to appose palm; holding with thumb, hook available for auxiliary function if needed; holding with hook, thumb as stabilizer.

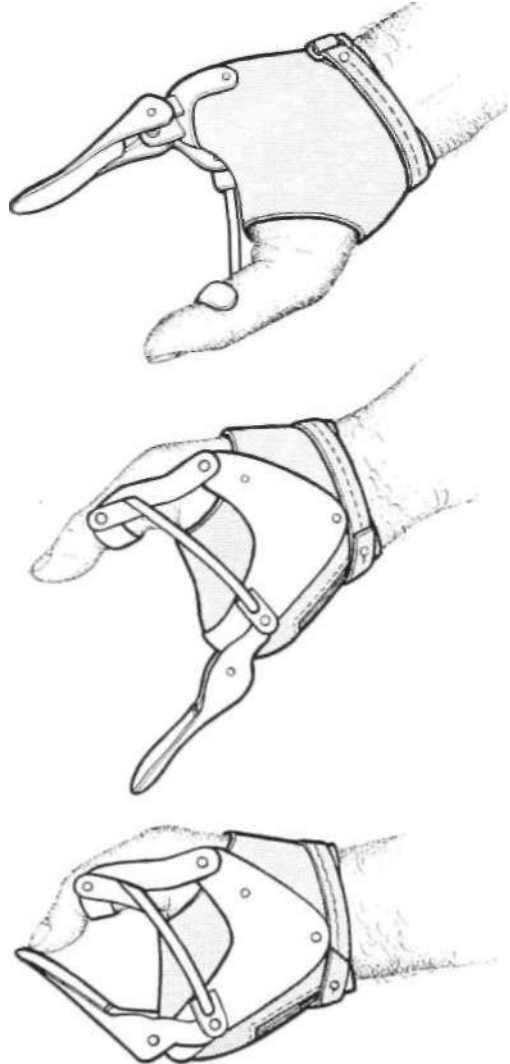


Fig. 44 Prosthesis for transmetacarpal amputation with retention of the thumb. Power supplied by the thumb activates metal finger, which is otherwise held in extension by a spring at its base. *Courtesy Navy Prosthetics Research Laboratory, U.S. Naval Hospital, Oakland, Calif.*

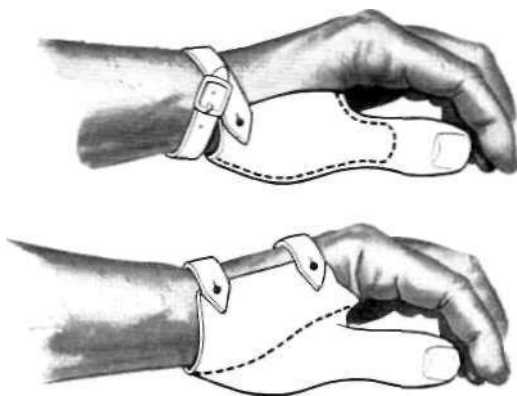


Fig. 45. Prostheses for partial or complete loss of the thumb. Fingers work in apposition to fixed member. Above, prosthesis for amputation of thumb at metacarpophalangeal joint, thumb web deepened surgically to provide cylindrical stump proximal to site of amputation. Below, variation suitable for amputation of thumb at carpometacarpal joint.

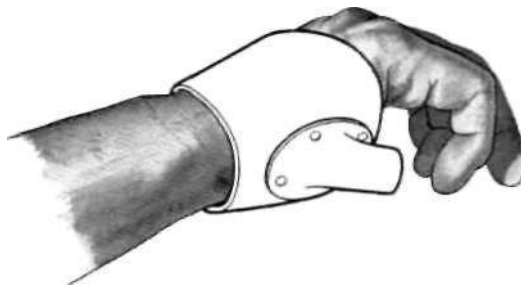


Fig. 46. One form of fixed prosthesis for total loss of the thumb.

large for the fingers themselves to encircle. A two-position thumb, such as the thumb from an APRL hand (3,4), can be used on a prosthesis for disarticulation of the thumb at the carpometacarpal joint. The result is that a larger selection of objects can be held in the hand.

Figure 47 depicts the application of a mobile artificial thumb, powered by the wrist, to a partial hand possessing only the little finger. Attached to a hand cuff, which in turn is hinged to a forearm cuff, the thumb pivots about an axis near its base. Linkage between

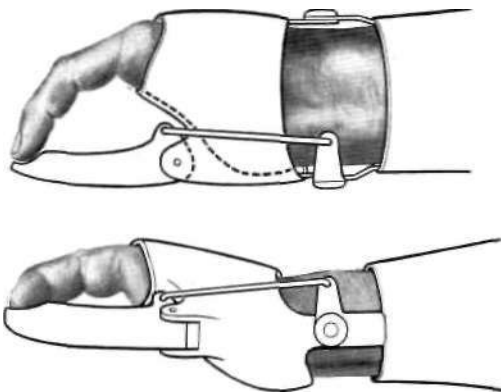


Fig. 47. Prosthesis for loss of all digits except the little finger. Laminated plastic socket, hinged to leather or plastic forearm cuff, supports plastic-covered metal thumb, which is so linked to forearm piece as to be driven by wrist motion. Little finger has been rotated surgically to provide better apposition with respect to prosthetic thumb. *Courtesy Robin-Aids Manufacturing Company, Vallejo, Calif.*

thumb and wrist hinge is such that wrist flexion causes the thumb to approach the little finger. In the example shown, the small finger has been rotated surgically toward the radial side of the arm to give better placement for apposition.

#### PROSTHESES FOR LOSS OF ALL DIGITS

In the case of a hand too crippled or too paralyzed to be of much use in the direct operation of a prosthesis, a split hook may be attached to a forearm cuff and positioned in the palm. This arrangement (Fig. 48) allows the palm to work against the hook for some types of prehension and still provides for the hook to be operated by shoulder harness in the usual way. The stainless-steel hand plate shown in Figure 49 provides a simple, light, and cool means of mounting a split hook to a hand stump that is too short to grasp objects without a prosthesis.

Still another way of accommodating for loss of all digits is to enclose the base of the hand in a leather cuff linked to a forearm cuff, a split hook being attached to the hand cuff (Fig. 50). The cuff and forearm members are connected by a rod working levers in such a

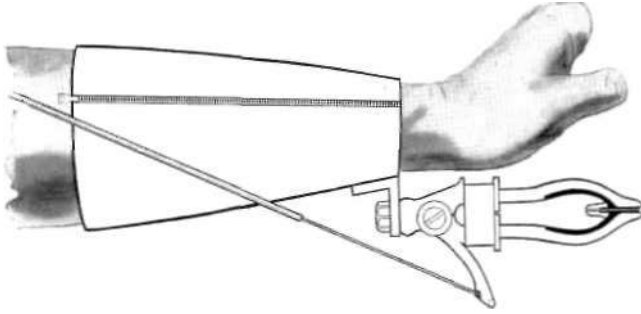


Fig. 48. Prosthesis for virtual loss of all digits. Palm can work against hook, or hook can be operated in conventional way by virtue of cable attached to shoulder harness.

way that, when the wrist is flexed, the split hook opens; extension of the wrist closes the hook.

#### NEW DEVICES FOR PARALYZED ARMS

For the paralyzed arm, many new devices have come forth in the past five years. They all have the same essential purpose—that of carrying the useful, or partially useful, hand to a place where it can operate to advantage. But in these cases there is an additional hurdle to be jumped. Whereas an arm prosthesis can be built to almost any desired weight, in the case of a paralyzed arm the weight of that arm must be overcome before motion can be reacquired. Equipment such as the shoulder suspension hoop, the locking-lever arm brace, the alternator elbow-lock arm brace, suspension slings, and single, double, or triple rocker feeders or arm balancers can do this job (10).

Once a paralyzed arm can be positioned in a place of usefulness, hand function must be restored, either by surgical or by prosthetic means. Some of the terminal devices intended for arm amputees can be utilized for patients with paralyzed or badly disabled hands. A good example of the management of the paralyzed hand is to be found in the application of the "Handy Hook" (P). It constitutes a simple but effective means of positioning a split hook in the palm of the hand and fasten-

ing it there to a metal or plastic palmar plate, which is held in place by straps around the dorsum of the hand (Fig. 51). In the event the wrist also is flail, a simple brace on the forearm constitutes a

suitable modification (Fig. 52).

For a hand that is lacking in one or more features of normal motor power but which retains valuable sensation, there is still another assistive device, the "Handy Hand" (P). Figures 53 and 54 show two variations out of numerous possibilities, each designed to accommodate specific motor losses (flexion or extension of fingers, flexion or extension of wrist, and so on). In Figure 53, finger opening may be brought about voluntarily (or, if necessary, by rubber bands), closure being


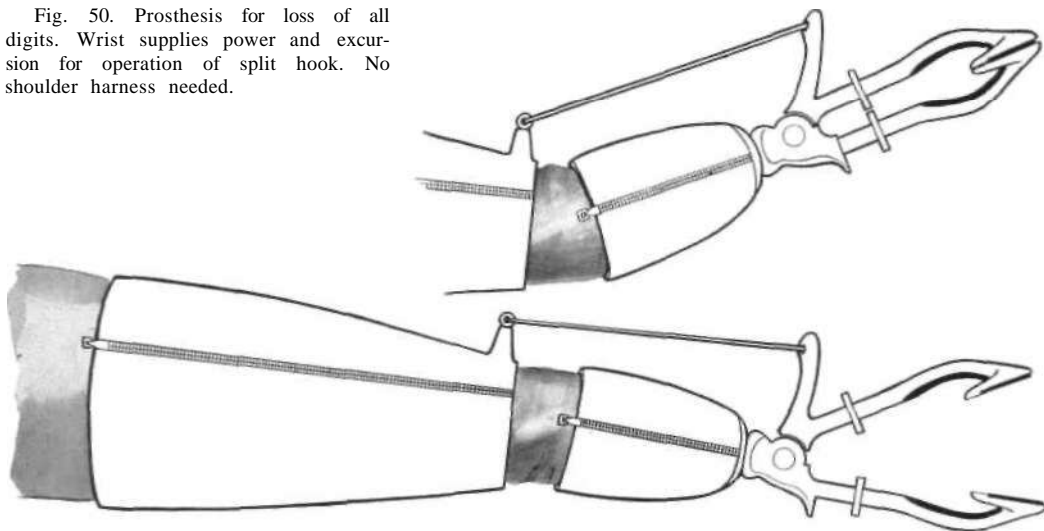


Fig. 49. Method of attaching a split hook to a short hand stump. Mobility of the wrist is maintained.



Fig. 50. Prosthesis for loss of all digits. Wrist supplies power and excursion for operation of split hook. No shoulder harness needed.



effected by shoulder harness. In Figure 54, active wrist extension effects finger closure.

#### CONCLUSION

So vast and so laden with potentialities is the subject of surgical reconstruction of the hand, and so also is that of partial hand prostheses, that a single article such as this can constitute only a very brief introduction to either. But even a brief review of some of

the recent advances, both in reconstructive surgery and in prostheses for partial hands, may offer valuable guidance in selecting the best procedure for any given case. In the absence of a well-developed literature, the whole field of work with partial hands is long apt to remain highly empirical and largely dependent upon the experience, judgment, and skill of individual surgeon and prosthetist. Since, unlike the more conventional amputa-

tion stump, the partial hand is invariably a special problem, the approach to its solution, whether surgical or prosthetic or both, also invariably calls for special departures. The most that can be said is that from long

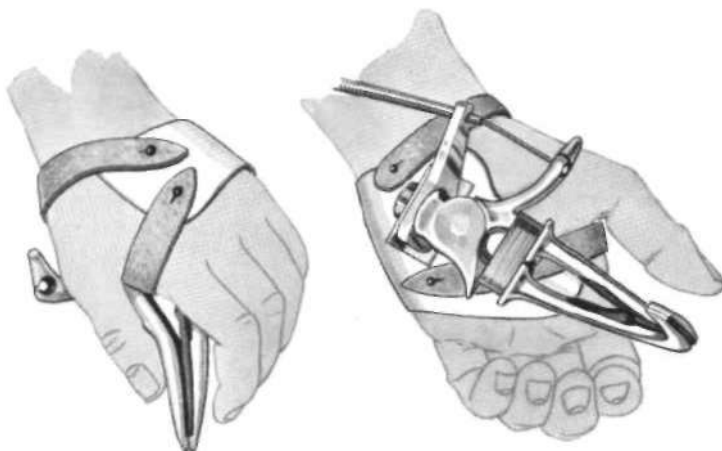


Fig. 51. The "Handy Hook" as applied to a flail hand. Positioned in the palm by means of a plate passing over the dorsum, it is powered by shoulder harness. Hand sensation is preserved. Courtesy Robin-Aids Manufacturing Company, Vallejo, Calif.

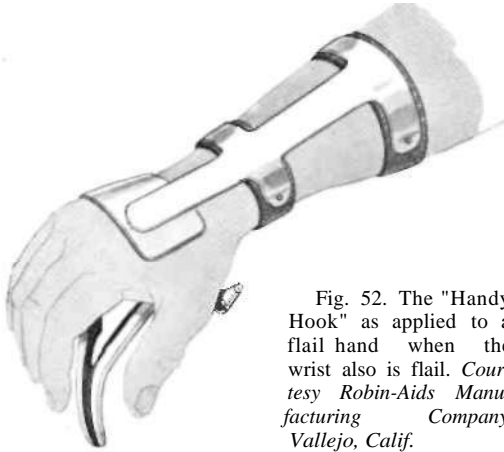

Fig. 52. The "Handy Hook" as applied to a flail hand when the wrist also is flail. Courtesy Robin-Aids Manufacturing Company, Vallejo, Calif.

practice and much trial and error it is possible to extract certain principles generally applicable to the more common types of hand losses.

In any event, it is apparent that the surgeon who would undertake reconstructive hand surgery ought first to be intimately familiar with the best that can be done with prostheses for partial hands. Similarly, the specialist in partial hand prostheses needs to be acquainted with what can be accomplished through surgery. Both, separately and together, must consider each case individually not only from the standpoint of the patient's life and work but also with a view toward his ability to afford the financial outlay incident to surgery and recuperation. Fortunately, insurance has in recent years played a large part in eliminating the economic considerations otherwise involved.

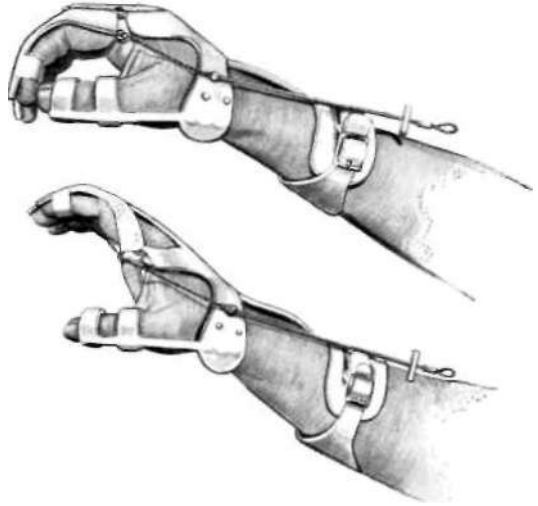


Fig. 53. The "Handy Hand" as applied to a flail hand when the wrist also is flail. Extension of the fingers may be effected voluntarily or, if necessary, by rubber bands. Flexion of the fingers is brought about by means of shoulder harness. Courtesy Robin-Aids Manufacturing Company, Vallejo, Calif.

The strongest argument that can be advanced for reconstructive hand surgery is that it preserves the highly desirable facility of tactile sensation. Among the disadvantages are the fact that the result does not always present the best cosmetic effect and the additional one that the reconstructed hand may not be able to perform heavy work as well as could a full prosthesis. The particular requirements of the individual therefore exercise a strong influence upon the choice between the partial hand and the wrist disarticulation. As has been seen, the most practical result is often best obtained through some combination of surgery and prosthetics, the two complementing each other in such a way as to provide a wide range of functional regain.

Of course there will always be hands with too much wrong with them to justify attempts at reconstruction. Where such appears to

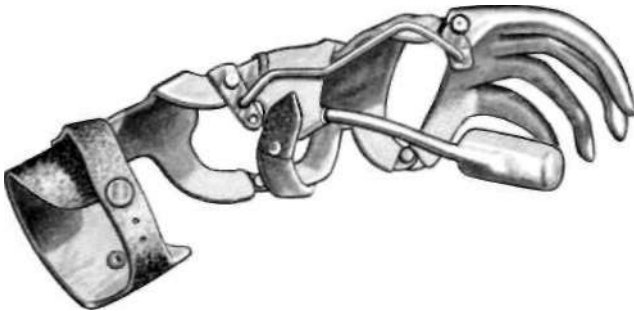


Fig. 54. The "Handy Hand" as applied when extensors of wrist and fingers are active, finger flexors inactive. Extension of the wrist effects flexion of the fingers. Courtesy Robin-Aids Manufacturing Company, Vallejo, Calif.

be the case, amputation at the lowest possible level, followed by application of a good, functional prosthesis, obviously offers the best solution. But in the face of a rapidly growing technique in hand surgery—including special manipulations with muscles, tendons, nerves, and vessels—it would appear wise always to choose the most conservative course possible. That would mean reconstruction whenever the anticipated result is likely to serve satisfactorily the needs of the individual concerned. The possibilities outlined here are representative of what might reasonably be expected under a given set of circumstances.

#### ACKNOWLEDGMENT

For much valuable information on partial hand prostheses that have proved successful, the author is indebted to George B. Robinson, of the Robin-Aids Manufacturing Company, Vallejo, Calif. The drawings accompanying this article are the work of George Rybczynski, free-lance artist of Washington, D. C.

#### LITERATURE CITED

1. Alldredge, Rufus H., and Eugene F. Murphy, *Prosthetics research and the amputation surgeon*, Artificial Limbs, September 1954
2. Bunnell, Sterling, *Surgery of the hand*, 3rd ed., Lippincott, Philadelphia, 1956.
3. Fletcher, Maurice J., *The upper-extremity prosthetics armamentarium*, Artificial Limbs, January 1954
4. Fletcher, Maurice J., and Fred Leonard, *The principles of artificial-hand design*, Artificial Limbs, May 1955.
5. Fletcher, Maurice J., and A. Bennett Wilson, Jr., *New developments in artificial arms*, Chapter 10 in Klopsteg and Wilson's *Human limbs and their substitutes*, McGraw-Hill, New York, 1954.
6. Kirk, Norman T., *Amputations*, a monograph from Vol. III of Lewis' *Practice of surgery*, W. F. Prior Co., Inc., Hagerstown, Md., 1944.
7. Navy Prosthetic Research Laboratory, U. S. Naval Hospital, Oakland, Calif., *Cineplastic above-elbow prosthesis (congenital bilateral arm amputation)*, Interim Progress Report [on] Research Project NM 007 084.26, 1 November 1954.
8. Pursley, Robert J., *Harness patterns for upper-extremity prostheses*, Artificial Limbs, September 1955.
9. Robin-Aids Manufacturing Co., Vallejo, Calif., *Functional arm bracing and artificial arms*, 1956.
10. Schottstaedt, Edwin R., and George B. Robinson, *Functional bracing of the arm*, J. Bone & Joint Surg., 38A(3):477;38A(4):841 (1956).
11. University of California (Los Angeles), Department of Engineering, *Manual of upper extremity prosthetics*, R. Deane Aylesworth, ed., 1952.