

Two-Stage Cast-taking Procedure for PTS Prosthesis

by Kurt Marschall, CP

Proper cast-taking and accurate measurements of a patient's remaining extremity, combined with careful evaluation and modification of the positive mold, are the most important steps in the fabrication and fitting of any prosthetic-orthotic device. Success or failure in prosthetic-orthotic fitting is directly related to the cast taken and the modifications incorporated in the positive mold.

It is my firm belief that the person taking the cast should also be the one to modify it. Ideally, the modification of any master mold should be accomplished as soon after cast-taking as possible. The reasons are obvious. It makes it possible to recall the characteristics of the patient's extremity and to pay special attention to particular landmarks and problem spots that have been identified. Long delays will only serve to wipe out the memory of these characteristics. Granted, the caseload in some facilities does not permit this ideal situation of an immediate cast-modification procedure. Therefore, it should be the aim that the cast-taker produce a cast that can be easily understood and interpreted by the person modifying it. In the case of the PTS cast, landmarks should be well identified, circumference and length measurements should be accurate and special consideration or conditions should be carefully recorded. These are preconditions for proper cast modification and subsequent fabrication of a superior fitting socket, and form the foundation of any successful below knee fitting procedure.

It is now well over twenty years since I first introduced, together with my colleague and partner, Robert Nitschke, CP, the American concept of the PTS prosthesis in Palm Springs, California. It now enjoys a widespread acceptance in the field of prosthetics and has become an integral part of the prosthetic armamentarium.

Since then, deviations from the original PTS concept, dictated by physiological reasons, geographic location or climactic conditions have been introduced. The Fillauer removable medial wedge,² as well as the removable medial brim version,³ are such a case in point. The supracondylar fitting with the anterior portion of the socket cut distal to the midpatella level, which thus sacrifices intimate contact with the quadriceps, should also be mentioned.

All of these different techniques have their place. They work well, if, as a prerequisite to socket fabrication, a cast of superior quality and accurate cast modification can be supplied.

Twenty years ago, we advocated a one step cast-taking technique, necessitating the use of a cast cutter in the posterior portion of the medial and lateral hamstrings for cast removal. The noise of the cast cutter, accompanied by some heat development when the blade oscillates through the cast, proved to be quite troublesome and sometimes frightening, especially to children and geriatrics. For these reasons we have employed for many years now a two-stage casting procedure in our facilities that produces a cast of superior quality with built-in characteristics that are easily identifiable in our positive molds prior to modification.

MEASURING AND CASTING PROCEDURE

1. Materials and tools necessary for cast-taking procedure (Figure 1):
 - 2 light cast socks
 - 1" elastic belt and 2 holding clamps
 - PTS caliper
 - A-P tension clamp
 - Bandage scissor
 - Goniometer



Figure 1. Materials and tools necessary for PTS prosthesis cast-taking procedure.

Modified Ritz stick
 Orthoflex plaster bandage, 4"
 Regular plaster of Paris bandages, 4",
 extra fast setting
 Revere rubber bands, size 33 or
 equivalent
 Otto Bock separation gel
 (Gipsisoliercreme) or vaseline

2. After positioning patient properly and comfortably on table, examine and palpate extremity carefully. Record findings on measurement sheet. Apply two light cast socks over patient's extremity and identify with indelible pencil all pertinent landmarks and bony protuberances (Figure 2).
3.
 - a. Record circumference at three levels: mid-patellar tendon, mid-portion and around distal end of extremity.
 - b. Record length of amputated extremity with modified Ritz stick (Figure 3).
 - c. Record M-L dimension with PTS caliper at widest margin of knee (Figure 4).
 - d. Record M-L dimension above the medial and lateral femoral condyles (Figure 5).
 - e. Record A-P dimension with knee relaxed and slightly flexed. The amount of flexion depends on the length of the remaining extremity. Seven–10 degrees is usually sufficient for medium sized amputations. Shorter ones may require more flexion (Figure 6).
4. Wrap the amputated extremity with Orthoflex bandage starting at distal end and terminating at the mid-patella level. Reinforce

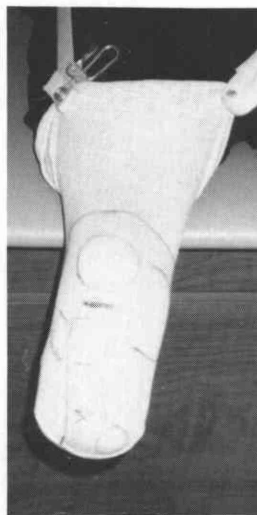


Figure 2. Identify all landmarks and bony protuberances.

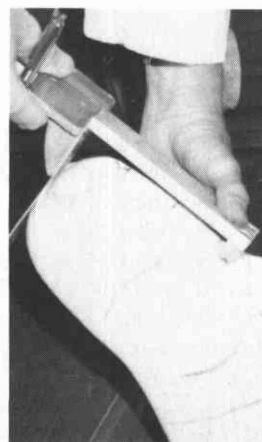


Figure 3. Record length of extremity with modified Ritz stick.

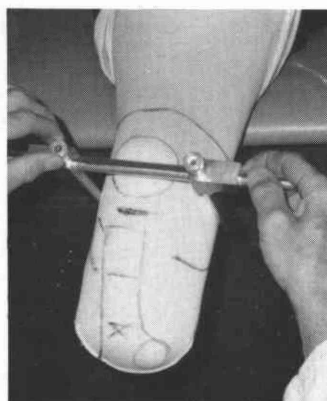


Figure 4. M-L dimension at widest margin.

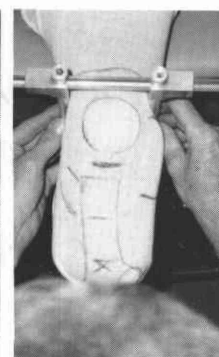


Figure 5. M-L dimension above medial and lateral femoral condyles.

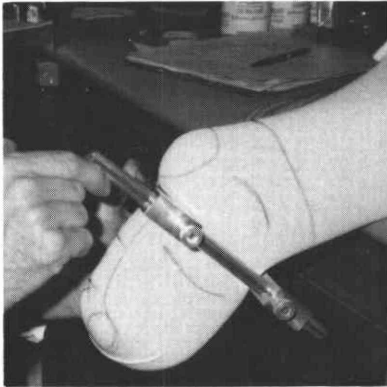


Figure 6. A-P dimension with knee relaxed and slightly flexed.

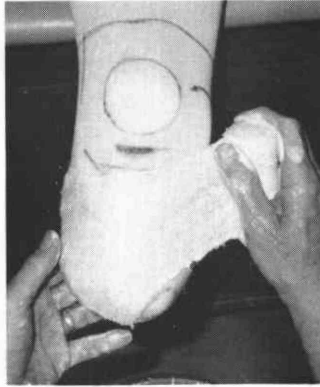


Figure 7.

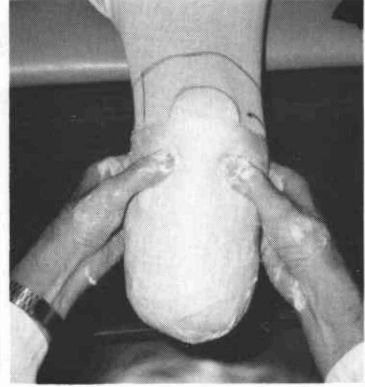


Figure 8.

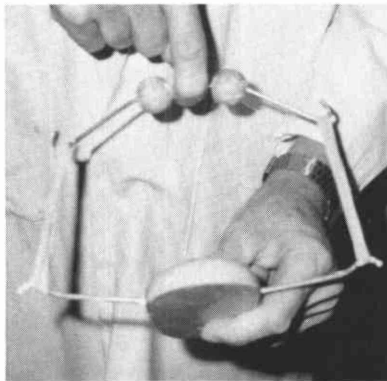


Figure 9. Apply A-P tension clamp.

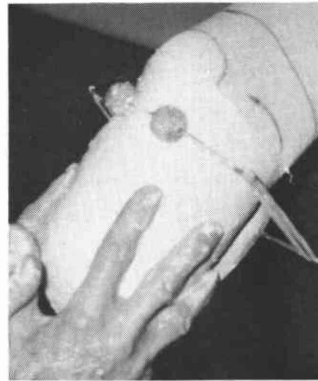


Figure 10.

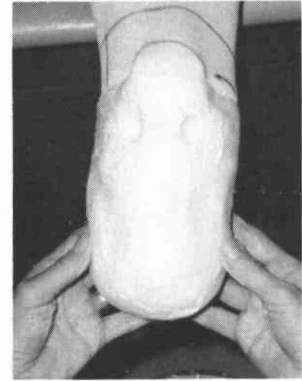


Figure 11.

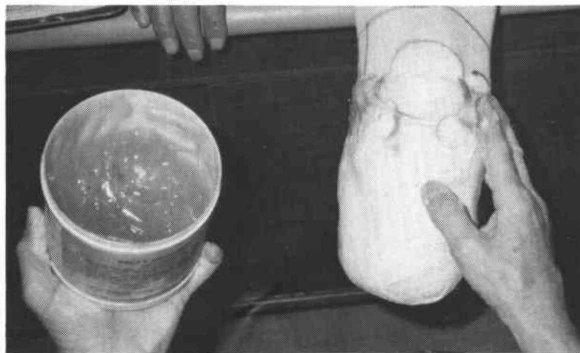


Figure 12.

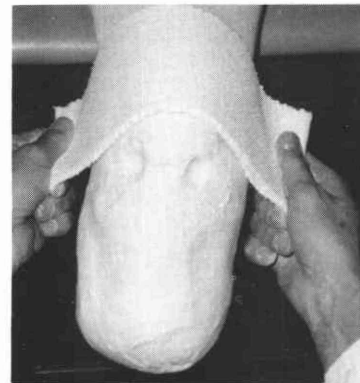


Figure 13.

with regular, extra fast setting plaster of Paris bandage, and identify with thumbs the patellar-tendon bridge (Figures 7 & 8).

5. With plaster of Paris cast still soft and moldable, apply A-P tension clamp (Figure 9). This makes it possible to shape the cast with both hands while it hardens, thus keeping later cast modifications to a mini-

mum (Figure 10). Please note clamp and hand-induced characteristics of hardened first stage of mold (Figure 11).

6. Use Otto Bock separating gel or vaseline and apply a thin layer to the proximal 1½" of the superior portion of the cast (Figure 12). Measure out six layers of 4" regular, extra fast setting plaster of Paris bandage or

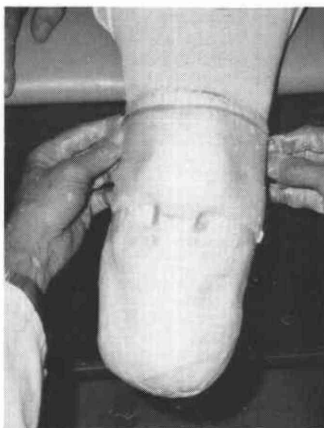


Figure 14. Apply two rubberbands to superior edge of wings.

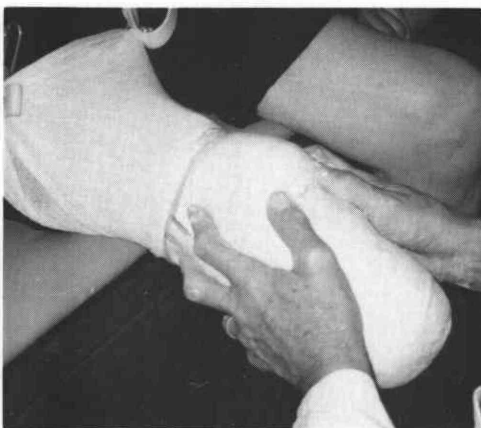

Figure 15. Apply sufficient pressure to reach the depth of the recorded narrow M-L dimension.

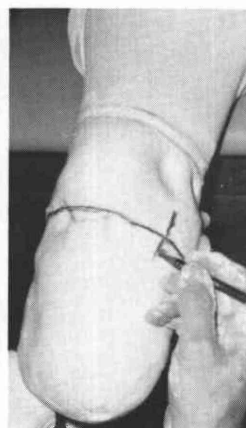

Figure 16. Mark juncture between first and second stage.

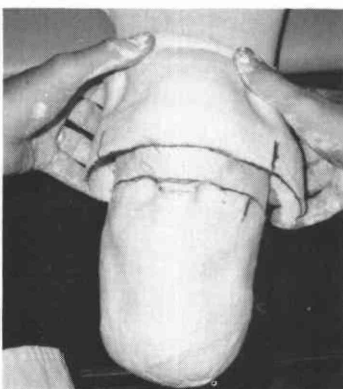


Figure 17. Carefully loosen and lift medial and lateral wings free.

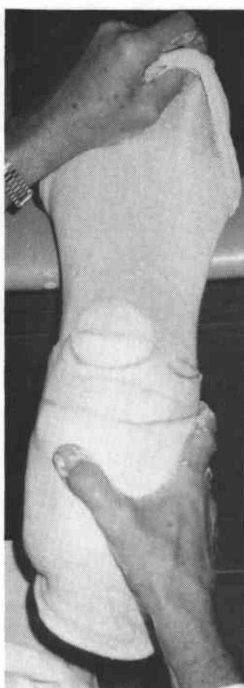

Figure 18. (right) Slowly remove first stage while pulling the bottom cast sock proximal.

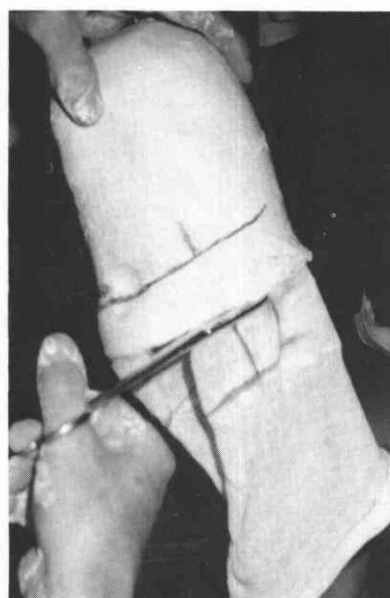


Figure 19. Cut off excess cast sock adhering to first stage.

splints, sufficient in length to reach slightly past medial and lateral hamstrings (Figure 13). Apply to patient's extremity, overlapping first stage cast by at least one inch and extending over the patella and covering quadriceps tendon by one inch. Use six inch wide splints if necessary. Apply two thin rubber bands to superior edge of wings (Figure 14).

7. Place thumbs in the indentations of the mid-patellar tendon bridge and use the index and middle fingers of both hands to

apply sufficient pressure to reach the depth of the recorded narrow M-L dimension just superior to the femoral condyles. The fingers should always straddle the ilio-tibial band on the lateral side (Figure 15).

8. After the second stage of the cast has set enough to hold finger impressions in place, remove the rubber bands and mark juncture between first and second stage with indelible pencil (Figure 16). Remove second stage by carefully loosening and lifting medial and lateral wings free (Figure 17).

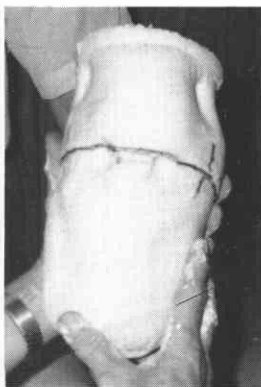


Figure 20. Join both stages together, matching the separate marks exactly.

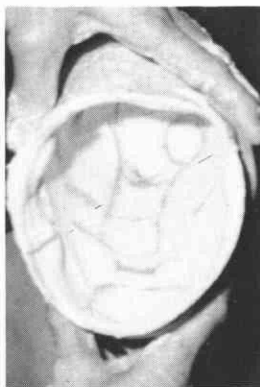


Figure 21. The negative wrap should display all landmarks clearly.

9. Reflect the top cast sock distally. Let patient's musculature relax completely. While pulling the bottom cast sock proximal, slowly remove first stage (Figure 18).

Cut off excess cast sock adhering to first stage (Figure 19).

10. Join both stages together again by matching the separation marks exactly (Figure 20).

While holding both stages securely together with the left hand, place plaster of Paris bandage about the juncture and wrap all the way to the top of cast.

11. The negative wrap should display all landmarks clearly (Figure 21). Check for correct flexion angle. Negative cast can now be filled.

During the cast-taking procedure, I make it a point to involve the patient by explaining each and every step. I use proper nomenclature and anatomical description of the remaining extremity. We should remember that each patient has gone through a very traumatic, cosmetically and functionally destructive surgical procedure. His or her spirits need to be lifted and encouraged. Most patients appreciate an intimate involvement in their prosthetic rehabilitation. Some of them even retain the knowledge gained during their cast and fitting procedures and answer subsequent questions on a sophisticated level. Treatment of your patient as a human being, rather than as a number among many makes being in this profession such an outstanding experience.

CONCLUSION

The importance of a good cast-taking technique has been stressed. Ideally, the positive mold should be modified by the cast-taker. In the absence of such a luxury, the cast modifier, with the aid of the measurements and the recording of special considerations, should be able to readily understand the characteristics that have been built into the cast. Proper cast modification will contribute immeasurably to good socket fit and superior function and performance by the amputee.

Where the above guidelines have not been followed, an inferior socket fit will result. In such a case, the cast-taking procedure should be repeated and a new socket should be fabricated. Successfully fitting 10 to 20 patients in a row does not make any of us an infallible super-prosthetist. Every once in a while we all have to admit defeat due to oversight of basic principles or failure to adhere to prescribed guidelines and procedures. These infrequent failures will keep us on our toes and make us humble again. But, admitting defeat or failure and correcting it without a moment's hesitation, will make you, in the eyes of your peers, in the eyes of your physician, but foremost, in the eyes of your patient, the better practitioner.

REFERENCES

- ¹Marschael, K. and Nitschke, R., "Principles of the Patellar Tendon Supracondylar Prostheses," *Orthopedic Appliance Journal*, Vol. 21, No. 1, March, 1967, pp. 33-38.
- ²Fillauer, C., "Supracondylar Wedge Suspension of the PTB Prostheses," *Orthotics and Prosthetics*, Vol. 22, No. 2, June, 1968, pp. 39-44.
- ³Fillauer, C., "A Patellar-Tendon-Bearing Socket with a Detachable Medial Brim," *Orthotics and Prosthetics*, Vol. 25, No. 4, December, 1971, pp. 26-34.

AUTHOR

Kurt Marschall, CPO is President of Empire Orthopedic Laboratories, a division of Rochester Orthopedic Laboratories, Inc., 249 East Adams Street, Syracuse, New York 13202.