

# The Past and Present Medical Significance of Hip Disarticulation<sup>1</sup>

HENRY E. LOON, M.D.<sup>2</sup>

Hip disarticulation, or amputation through the hip joint, is one of the most drastic surgical removals known to medicine. It is seldom justified as other than a last-resort, lifesaving measure and, as compared to other amputations, is seldom performed. Because of its severity, and because it has been used only for patients already on the verge of medical disaster, it has been attended by discouragingly high mortality rates throughout its 200-year history. By the same token, however, the record of the changing need for hip disarticulation is a record of medical progress against fatal disease and trauma of the lower extremity. Whereas hip disarticulation was first used extensively against gangrene or the ever-present threat of generalized infection, it is now most frequently one of the ultimate weapons against cancer. Moreover, the operation has lost much of its fearsomeness as general medical knowledge and surgical skill have increased and as the hope for prosthetic rehabilitation of these patients has become brighter.

By presenting the medical aspects of hip disarticulation in historical perspective, it is hoped to show here how the pathological conditions indicating hip disarticulation have changed as medical science has progressed, how the operative dangers of hip disarticulation have been largely overcome, and how the

surgical fashioning of the stump (within the limits imposed by injury or disease) has helped in the prosthetic rehabilitation of patients. Finally, there is appended a discussion of the recent interest paid to systemic effects that may accompany any major loss of limb.

## HISTORICAL BEGINNINGS

Until the mid-eighteenth century, surgeons considered themselves helpless to treat complicated fractures or suppurative diseases of the upper part of the femur, let alone malignant growths in this region. Death from septic complications, gangrene, or, in the case of cancer, metastases, was the almost inevitable outcome of these conditions.

Surgical disarticulation of the hip was apparently first conceived by Sauveur Francois Morand, a leading French surgeon of the early eighteenth century, and was formally proposed in 1739 by two of his pupils (36). Long before the first true surgical disarticulation, however, the hip of a boy of 14 was nearly disarticulated by gangrene which resulted from his having eaten diseased rye. Observing the thigh to be connected to the trunk only by the round ligament, the sciatic nerve, and some shreds of tissue, the French surgeon Lacroix (44,65) cut these with scissors. The other leg, similarly affected, was cut from the hip in the same manner four days later, and the patient survived another 11 days. This case gave a great impetus to discussion of the matter. In 1759, the Royal Academy of Surgery offered a "double prize" for the best essay on the following subject: "Dans le cas ou l'amputation de la cuisse dans l'article paroitroit l'unique ressource pour sauver le vie a un malade, determiner si l'on doit pratiquer cette opera-

<sup>1</sup>A contribution from the Biomechanics Laboratory, University of California, San Francisco and Berkeley, aided by U. S. Veterans Administration Contract VAm-23110 and U. S. Public Health Service Grant RG-4856(C).

<sup>2</sup>Research Orthopaedist, Biomechanics Laboratory, University of California Medical Center, San Francisco.

tion, et quelle seroit la methode plus avantageuse de la faire."<sup>3</sup> Of 44 essays submitted, 30 were in favor of performing the operation (36).

Not until 1774 was it proved that death on the operating table was not a necessary consequence of this formidable operation. In that year, the first true surgical disarticulation of the hip was performed by William Kerr (1), of Northampton, England, on an 11-year-old girl who had a tumor of the thigh and symptoms of pulmonary tuberculosis.<sup>4</sup> The disarticulation had probably not greatly influenced the course of the disease, and Kerr concluded his presentation optimistically (p. 342): "With regard to the expediency of the operation, I am so much convinced of it in certain cases, that in such I shall not, for the future, hesitate to perform it when they occur."

Another disarticulation said to have been performed at about the same time by Henry Thomson at the London Hospital apparently terminated fatally (58), and the operation was not reported again for nearly 20 years. The Wars of the French Revolution and the Napoleonic Wars brought with them a new series of hip disarticulations.

#### SHIFTS AND CHANGES IN INDICATION OVER Two CENTURIES

Although the earliest hip disarticulations were performed for disease, in the following 100 years many more were done for gunshot wounds than for any civilian cause. Up to the end of the American Civil War, nearly two and a half times as many military as civilian operations had been reported from Europe and America, as recorded by Otis in *The Medical and Surgical History of the War of the Rebellion* (63). Since that time, the situation appears to have been reversed again owing to the decreased necessity for the operation fol-

lowing battle injuries and its increased use to remove malignant growths. It would be instructive to be able to compare hip disarticulations of military and of civilian origin—as to exact incidences and indications—throughout the history of the operation, but unfortunately information is incomplete and many difficulties of interpretation arise. Nevertheless, a comparison of the indications given for each group points up the necessity of considering the two categories separately.

#### INDICATIONS IN MILITARY SURGERY

The military surgeon has always been concerned mainly with trauma and ensuing infection, although infection plays a progressively less important role than formerly. In 1812, Dominique Jean Larrey (28), the famous French surgeon and personal physician of Napoleon, who himself (Larrey) performed seven of the early disarticulations, stated the indications for the operation in military surgery as follows:

1. A torn-off limb, or great laceration of the limb so close to the upper articulation that amputation in continuity would not be possible.
2. Fracture of the femur in the vicinity of the trochanters, accompanied by a rupture of the femoral artery or of the sciatic nerve.
3. Massive gangrene of the lower extremity extending to the vicinity of the upper articulation, as a result of extensive wounds of the soft tissues.

At the time of the American Civil War, these indications were still considered valid, and Otis (63, p. 167) repeated the first two almost verbatim. Today, however, most severe fractures, and even many comminuted fractures, of the upper end of the femur, if not associated with irreparable vascular damage, can be treated conservatively. Most of the major amputations of extremities in World War II were the result of such extensive traumatic injury that no improvement in surgical technique could hope to effect repair. According to DeBakey and Simeone (12), 69 percent of the 3177 major amputations performed in the European and Mediterranean Theaters were due to extensive trauma (by which was meant complete or nearly complete severance of the limb or part of the limb), 12 percent to infection, and 19 percent to major arterial injury.

<sup>3</sup> "In a case in which amputation of the thigh at the articulation with the hip bone appears to be the last resort for saving the life of a sick man, to determine whether this operation should be performed, and what would be the most advantageous method of doing it."

<sup>4</sup> Or possibly a metastatic cancer of the lungs. At her death, 18 days after operation, an autopsy showed them to be "almost totally reduced to matter."

The relatively small percentage of amputations due solely to major arterial injury could probably now be reduced still more because of new techniques of repair and grafting of blood vessels. Some successful cases were reported from the Korean War, and knowledge is further advanced today (10, p. 155).

Statistics on the specific indications for the 56 recorded cases of hip disarticulation from World War II (3) are at present not available. The implications of the records seen is that the majority were traumatic amputations. For instance, of the 154 wounds of the hip joint observed between D-Day and VE-Day at the 802nd Hospital Center, none was treated by disarticulation. Regarding the incidence of infection, there was no report of rapidly spreading hemolytic streptococcal or staphylococcal infection, such as still occurred in World War I (10, p. 239). At the 802nd Hospital Center, infection occurred in 9 of 29 injuries of the femoral head or neck. Although these were cases of persistent, long-lasting infection, leading in two cases to death, no hip disarticulation was performed. Usually this tendency toward conservatism was justified, but in looking back, the Office of the Surgeon General has modified this attitude in the following statement (10, p. 245):

1. When there has been great mechanical destruction of the bone and soft parts and when retained foreign bodies carrying fragments of clothing cannot be removed, foci of infection are maintained for indefinite periods of time.

2. A prolonged delay before amputation merely results in exhaustion of the patient, so that, when the operation is eventually performed, it often poses a serious threat to life. . . . It must be assumed that patients with large areas of mixed, penicillin-resistant infection deteriorate every day that they live and that their chances of survival after major surgery become progressively less as time passes. . . .

4. Observation of numerous instances of pyoarthrosis of the hip joint at United States Army amputation centers made it clear that when the sciatic nerve is lacerated the indication for early disarticulation of the hip is particularly strong.

Fulminating gas gangrene is still an indication for amputation, but its incidence has been tremendously reduced by the employment of prompt and thorough debridement and the administration of antibiotics. It is impossible to determine from the available statistics

whether any hip disarticulations were performed because of this infection.

To sum up, in military surgery hip disarticulations—like other major amputations—appear to be performed today primarily when the limb is completely or almost completely severed from the trunk. To these traumatic amputations must be added those cases in which disarticulation is necessitated by major injury to the blood vessels or to the main nerve trunks (particularly the sciatic) and those in which multiple foci of antibiotic-resistant infection cannot otherwise be eliminated. That the number of hip disarticulations has not been greatly reduced in comparison with former wars is testimony to the increased destructiveness of modern weapons; the type of injury which used to necessitate hip disarticulation can usually be treated conservatively today.

#### INDICATIONS IN CIVIL SURGERY

The civilian surgeon has also always been concerned with trauma, but disease, and especially malignant disease, has played an increasingly important role. In 1839, Velpeau (65, p. 639) stated the indications for hip disarticulation in peacetime as follows:

A comminuted fracture, a necrosis, caries, osteosarcoma, spina ventosa, or any incurable degeneration whatever, of the femur, extended above its shaft, or gangrene, or any other disease in fact which has progressed nearly as high up as the haunch, and which is of such serious character as to demand amputation, will claim disarticulation provided the cotyloid cavity and the bones of the pelvis are not affected.

The major change in indications from the nineteenth to the twentieth century is best seen from a comparison of nonmilitary hip-disarticulation cases. It may be seen from Figure 1 that, although many of the conditions listed by Velpeau might today be considered indications for hip disarticulation, they do not in practice occur very often. Cancer is *the* indication now, whereas in the early period it was one among a number of causes. The indications given by Smith (53) for his historical survey of cases fall into the following categories: malignancy, 13; severe crushing injuries, 8; suppurative diseases of the femur, 7; tuberculosis, 4 (tubercular lesions of the bones,

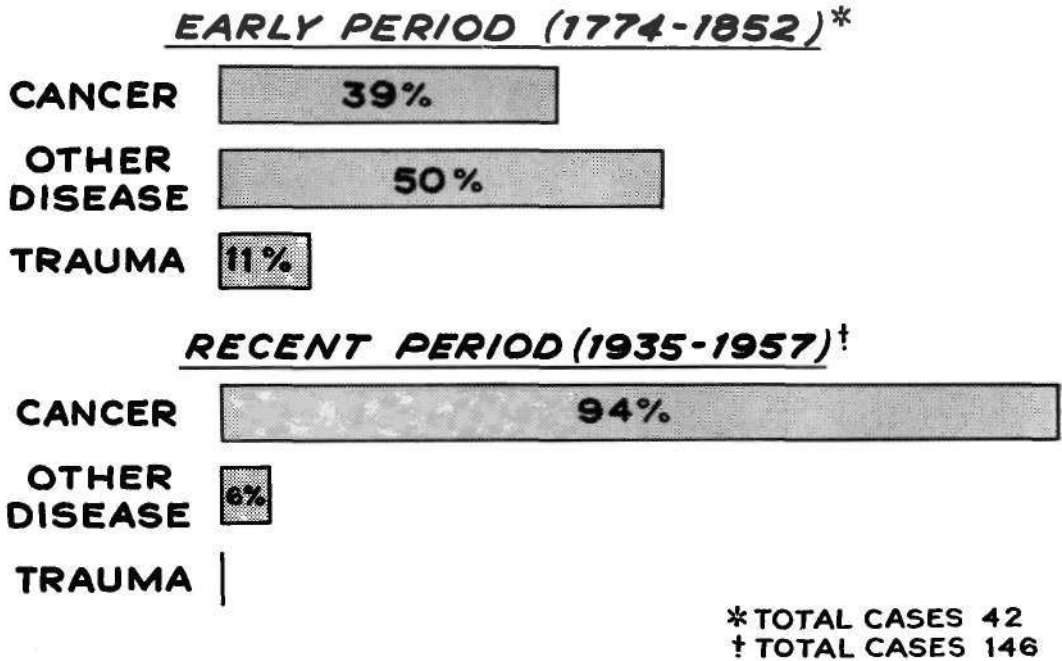


Fig. 1. Comparison of early and recent indications for hip disarticulation in peacetime. Data for the early period were taken from a compilation by Stephen Smith (53) of all known cases of hip disarticulation to 1852. Wartime operations and those for which the indication was not known were eliminated. Data for the recent period were derived from articles indexed under *Amputations* in the *Quarterly Cumulative Index Medicus* from 1935 through 1951 and in the *Current List of Medical Literature* from January 1952 through August 1957. Again, wartime operations and those for which the indication was not stated were eliminated.

3; tuberculoma of the thigh, 1); gangrene, 3; miscellaneous causes ("diseases of the femur," "coxalgia," pain, exostoses), 7.

Four of the tumors which Smith gave as indication were not classified by him as malignant. But from the description of the course of the disease they appear to have been, and they are therefore here grouped under malignancy. This is only one example of how difficult it is to determine with any certainty what the true indications for these early operations were. Another example is Kerr's case (page 5). Smith, following Kerr's own diagnosis, recorded the indication as tuberculosis; yet from the description of the case it seems conceivable that the patient had a malignant growth in the upper end of the femur and the innominate bone with metastases to the lungs.

Methods of diagnosis are greatly improved today, but it is no less difficult to obtain

reliable statistics on recent hip disarticulations. Cases that do not present striking medical or surgical aspects are no longer reported in the literature. In this country, unfortunately, no survey of the total number of amputees has ever been made, but even in countries like Germany or Great Britain, where the government has made such surveys for the larger categories of amputations, no information on the incidence of hip disarticulations, let alone the indications for them, seems to be available.

In a literature survey covering the period from January 1935 through August 1957, there were reported (Fig. 1) 146 civilian hip disarticulations for which the indications were given. Of these, 138 (94 percent) were done for malignancy {4,9,17,18,20,25,29,30,34,39,41,42,45,52,54,60}. Two were done for tuberculosis (30) and one each for osteomyelitis following an injury (24), phlegmon of thigh and general

septicemia following an injury (55), a suppurative process (etiology not stated) of the coxo-femoral articulation (7), actinomycosis (20), gangrene caused by thrombosis (34), and paralysis and contracture caused by an extradural abscess (34). It is a little surprising that, of all the reported civilian hip disarticulations, none was done primarily for trauma. I have myself seen one patient whose hip was disarticulated because of injuries in peacetime, and I am certain that there must have been a few others.

Fortunately, not all malignant growths, even in the upper part of the thigh, call for such drastic treatment as disarticulation of the hip. In some cases wide excision of the neoplasm suffices to remove it entirely. The decision as to whether or not to disarticulate depends upon the site and the type of the neoplasm. The indications upon which modern surgeons agree are well stated by Pack and Ehrlich (40, pp. 966-969), and the reader interested in these details is referred to that excellent paper.

#### INCIDENCE RELATIVE TO ALL LEG AMPUTATIONS

Comparison of the number of hip disarticulations with total numbers of lower-extremity amputations shows still more clearly how seldom hip disarticulation is performed. It has now become much rarer in military than in civilian practice. During the American Civil War (63, pp. 870-871) 86,413 wounds of the lower extremities were recorded. In 12,605 of these cases (less than 15 percent), the wounds resulted in major lower-extremity amputations. Of these, 66, or 0.5 percent of the amputations, were hip disarticulations (Fig. 2). In World War II (3, pp. 193-194), 248,000 wounds of the lower extremities were recorded. Of these, 12,612 (5 percent) are estimated to have resulted in major amputation. Fifty-six, or 0.4 percent, of the amputations are estimated to have been hip disarticulations. Thus the percentage of hip disarticulations in relation to total lower-extremity amputations has changed very little; it has remained small. Both the number of hip disarticulations and the number of lower-extremity amputations have, however, de-

creased greatly relative to the number of wounded.

In civilian cases the ratio of the number of hip disarticulations to all major lower-extremity amputations is probably somewhat higher but still less than 2 percent. Thus, of 70 lower-extremity amputees who underwent amputation or were treated at the University of California Medical Center from 1941 to 1955, only one had had a hip disarticulation (26). Of 663 patients with major lower-extremity amputations who have passed through the Veterans Administration Hospital in Oakland since the end of World War II, eight have had hip disarticulations (26). Even the records of an institution treating predominantly cancer patients show a very small number of hip disarticulations. The Bone Tumor Service of the Memorial Center for Cancer and Allied Diseases in New York City reported only 15 hip disarticulations from 1930 to 1946 (11), a fact which suggests that even today this operation is done only to forestall certain death.

#### THE LONG STRUGGLE TO REDUCE MORTALITY

There was good reason why hip disarticulation was not attempted, or even conceived, until the eighteenth century. The surgical skills which had been developed up to that time were still grossly inadequate for an operation attended by so much danger of hemorrhage and shock.

#### OPERATIVE MORTALITY

When we consider that the operation had to be done as fast as possible, without benefit of anesthesia or knowledge of asepsis, it is surprising how many of the earliest patients survived even a few days or weeks. Larrey (28), who was probably one of the most skilled surgeons of his time, has recounted cases in which, after ligating the femoral vessels together, he completed the procedure in 14 to 15 seconds. To achieve this speed, he used only four knife strokes. He drove a blade perpendicularly between the base of the femoral neck and the tendinous attachments of the lesser trochanter until it emerged posteriorly and, with an oblique downward stroke, cut the medial flap; raised the flap proximally to expose

the articulation and with a stroke of the bistoury cut the articular capsule; abducted the thigh (nearly dislocating the head of the femur) and in a stroke cut the interarticular ligament; and with a downward and outward stroke of a small straight knife cut the lateral flap. The remaining arteries were then ligated. Larrey did not consider it necessary to suture

the muscles. If there was no "irritation," the subcutaneous tissues and the skin were approximated with a few retention sutures. The edges of the wound were further drawn together by compresses dampened with red wine, and a large bandage was applied.

Larrey reported that his first patient survived the operation well but a few hours later

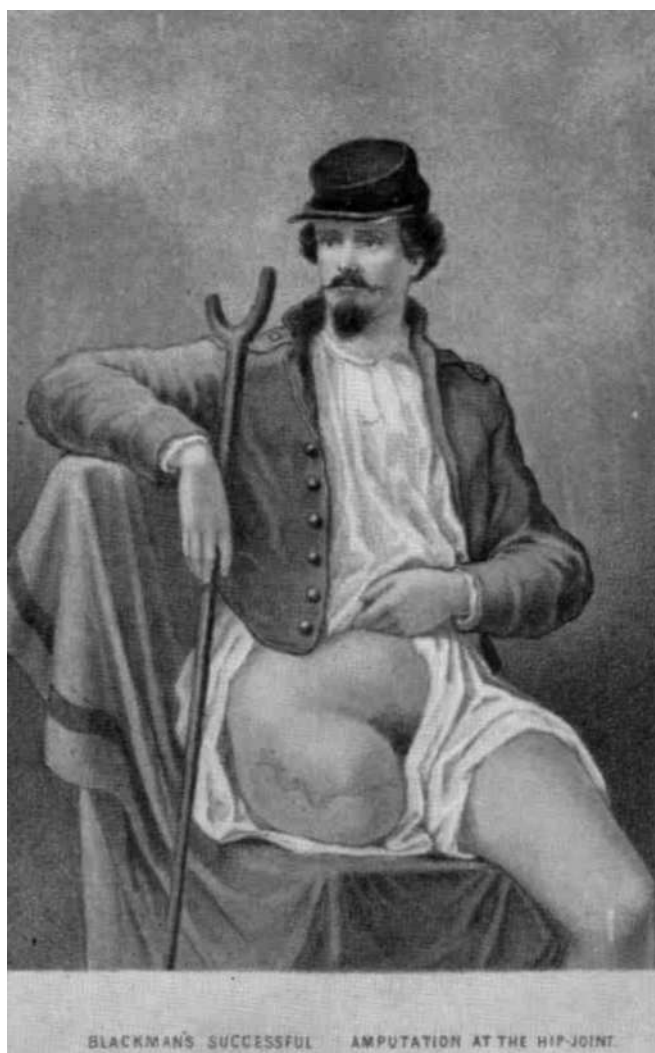

Fig. 2. One of the few survivors of disarticulation of the hip during the American Civil War. Note the large amount of soft tissue in the stump. From Otis (62).

had to follow the army in a 24-hour forced march in winter, so that he died presumably of cold and exposure. His second patient also seemed well on the road to recovery when, six days postoperative, a soldier with the plague was bedded on the same straw mat with him. Larrey's patient became infected and died within 24 hours.

The fate of these patients, who died not as a result of the operation itself, shows how difficult it is to establish the date of the first "successful" hip disarticulation. These two, together with others in which death occurred within a year after operation, were in early mortality statistics classed as fatalities.<sup>6</sup> On the other hand, there are no verifiable records of several of the early hip disarticulations claimed by later authors to have been successful. Otis on whose two works (62,63) the early figures given here are based, pointed to other frequent sources of fallacies in surgical statistics. He said (62, p. 6):

The desire for distinction of ambitious operators sometimes tempts them to report successful results prematurely, and to fail to record unfortunate cases. Feverish partisans of particular operative procedures, in accumulating statistics, not unfrequently evince an unpardonable disregard for the fundamental rules of evidence, and admit testimony abounding in transparent fallacies. Some writers, in their zeal to gather together numerous observations, group those that are very dissimilar, and deduce inferences from the collection that are pertinent only to particular cases.

He stated that in his own report the authenticity of cases was scrutinized and that doubtful cases were rigidly excluded (62, p. 7). Insofar as the records of earlier operations Otis recorded have been checked, he was indeed conscientious; yet in evaluating his figures it is essential to bear in mind all the limitations of this early material.

According to Otis (62, p. 18), 111 known civilian cases of hip disarticulation were reported from Europe and America to the end of the American Civil War. Of these, 46 were considered successful and 65, or 59 percent, terminated fatally. In military surgery (63, pp. 127, 163), 254 authenticated hip disarticulations were reported, with 28 recoveries,

225 deaths, and one result unknown—a mortality rate of 89 percent. Of the 187 patients who underwent hip disarticulation prior to the American Civil War, 17 survived, giving a mortality rate of 91 percent. In the 67 cases occurring during the Civil War, 11 of the patients recovered—a mortality rate of 84 percent.

In spite of this extremely high mortality rate, disarticulation gave better results than did more conservative methods of treatment for complicated fractures of the upper end of the femur. Of 252 patients with intracapsular shot fractures who were treated conservatively during the American Civil War, three recovered, giving a mortality rate of 99 percent (63). Fifty-five excisions of the femoral head resulted in a mortality rate of 91 percent (63).

The mortality rate did not improve materially until well after the general introduction of asepsis in the 1880's. In 1878, Farabeuf (14), when presenting his method of disarticulation to the Societe de Chirurgie in Paris, cited a still-persisting death rate of 75 percent. The American surgeon Wyeth (67), writing in 1890, mentioned "the terrible death-rate after hip-joint amputation."

### *Improvements in Surgical Technique*

After deaths from complications of infectious processes had been somewhat brought under control by the general introduction of aseptic surgical procedures, surgical shock still accounted for a large number of the operative deaths. A main contributing factor was hemorrhage.

*Reduction of Hemorrhagic Shock.* The arteries to the upper part of the thigh and the gluteal region branch out from several main trunks (Fig. 3), so that it is much more difficult to control the flow of blood for a hip disarticulation than for a thigh or leg amputation. Methods attempted for control ranged from a high tourniquet placed about the upper end of the thigh to compression of the aorta.

An ordinary touniquet is difficult to apply satisfactorily for a hip disarticulation. Placed about the thigh at the groin, it not only does not control bleeding from a number of the main vessels but it also slips out of place easily after enucleation of the proximal end of

<sup>6</sup> Thus the figures that follow are not statistics of operative or even hospital deaths alone.

the femur. For this reason, there were developed various devices for holding a tourniquet in place, the best known being Trendelenburg's (61) and Wyeth's (67) systems of pins. In both procedures, long steel pins were driven through the soft tissues to prevent slippage of rubber tubing used to constrict the tissues.

Of the more radical methods for compression of the parent trunks, some, such as a Davy's lever introduced through the rectum for the compression of the aorta, were dangerous, and they were not always reliable (49). Other authors recommended making an abdominal incision and temporarily compressing (32) or lifting (17) or even permanently ligating (6,22) the common iliac artery. The latter procedure has been recommended as recently as 1954 (18), but it is not commonly used today. Many surgeons hesitate to add to the system an additional shock by making an incision into the abdominal cavity.

In general, more conservative measures are and have been advocated. Although initial ligation of the femoral vessels does not provide a completely bloodless field (because of the many anastomoses from the obturator and gluteal arteries), it has usually been considered the most satisfactory method. As we have seen, Larrey in his early operations recommended preliminary ligation of the femoral artery and vein, and regardless of the type of incision this has been common practice to the present day. Farabeuf (15), whose procedure is still widely used, especially in Latin American countries, recommended an anterior racquet incision. The stem of the inverted Y should be over the point at which the femoral vessels pass under the inguinal ligament, and the artery and vein are sectioned and ligated before proceeding with the operation. Farabeuf claimed that other arteries could satisfactorily be cut and compressed by assistants as they

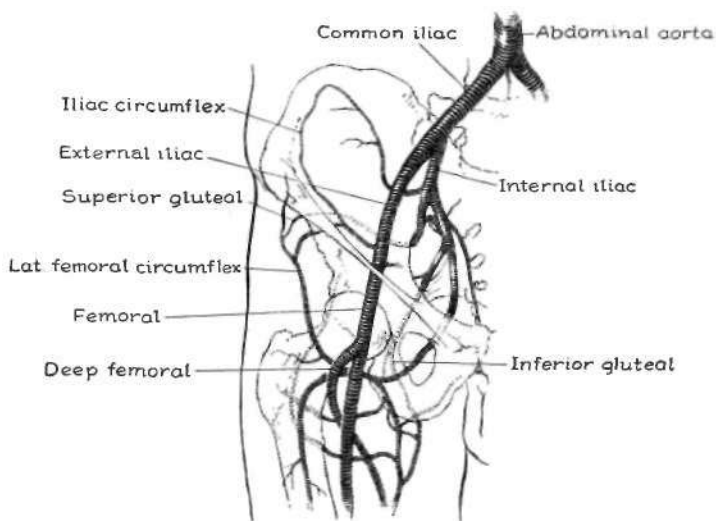


Fig. 3. Arterial system in the hip and upper part of the thigh. Redrawn, by permission, from *Gray's Anatomy*, 26th ed., Lea & Febiger, Philadelphia, 1954. The original appeared in Eycleshymer and Jones' *Hand Atlas of Clinical Anatomy*, Lea & Febiger, Philadelphia, 1925.

were encountered and then ligated before closing the wound. Marquardt (33) in a recent book stated that in Germany it is considered best to follow Angerer's two-stage procedure (2), in which ligation of the femoral artery and vein is done through an incision in Scarpa's triangle one or two days before the proposed hip disarticulation. This expedient allows the vessels to become thrombosed so that there is little loss of blood during the disarticulation itself.

Finally, blood may be conserved if, after ligation of the artery, the leg is elevated for several minutes to allow maximal drainage to the trunk before ligation of the vein (11,19,25,27,40).

In addition to careful hemostasis, it is helpful to section the muscles, wherever possible, in the avascular areas close to the tendinous origins or insertions rather than through the muscle bellies. This principle, proclaimed by Callander (8) in 1935 for his amputation just above the knee, has been applied to hip disarticulations by Leriche (30), Boyd (5), Slocum (51), and Piquinela (42). In the days when speed of operation was the primary consideration, the principle was necessarily violated.



If guillotine operations are excluded, it is hard to imagine a faster method than Larrey's, but cutting each flap with a single stroke, as Larrey did, meant sectioning the muscles through the richly vascularized bellies, thus contributing greatly to hemorrhage and shock. He was, of course, caught on the horns of a dilemma for those times, because speed, too, was essential to lessen shock.

*Other Techniques for Avoiding Shock.* Even in cases in which there has been no infection or excessive hemorrhage, shock often occurs. Bustos (7) gave this as reason for believing that conditions which could cause pain played the major role in causing shock. Gentle handling is considered essential by most modern surgeons. Layer-by-layer dissection, using a scalpel, was recommended by Petrovskii (41). Caprio (9) recommended the use of an electric scalpel, with which he claimed that he could carry out the whole operation without even turning the patient over, as is usually done.

Many surgeons have taken precautions to avoid shock that might result from overstimulation of the sciatic nerve. Since this large nerve trunk runs through the posterior portion of the thigh, it is ordinarily not sectioned until the latter part of the operation and is in the meantime subjected to a variety of tensions, particularly after the dislocation of the femoral head, when the half-severed limb hangs from the trunk, connected only by this nerve and associated soft tissue. Various methods for overcoming this problem have been suggested—proper support of the limb throughout surgery to avoid these tensions (54); injection of the nerve with procaine before sectioning it (5,7,9,11,20,30,34,37,40,41,51); and even, in a debilitated case, section of the sciatic nerve (after injection with procaine) almost at the start of the operation (7). In 1917, Morris (37), using spinal anesthesia, began his operation by injecting the sciatic nerve with procaine through a small posterior incision and then proceeded through anterior incision with what is usually the first part of the operation. He stated that no shock was observed during the ensuing disarticulation.

Recently, the use of spinal anesthesia has

been questioned (40) on the grounds that hypotension results, which could be dangerous in view of the seriousness of hip disarticulation. However, hypotension does not occur routinely when the level of spinal anesthesia is so low that the splanchnic nerves are not anesthetized (43). Injecting the sciatic nerve may appear superfluous if spinal block has been performed prior to the operation. It seems to be done as an additional precaution and as a means of blocking any afferent fibers that, traveling via the sympathetic chain, may enter the cord above the level of spinal anesthesia.

A two-stage operation is sometimes advisable for patients who are in very poor condition. We have already mentioned Angerer's procedure of ligating the femoral vessels one or two days before the disarticulation, a method which aids in avoiding shock by reducing blood loss. Even a three-stage procedure has been recommended (23). In most cases today, however, the operation is performed in one stage only.

#### *Improvements in Adjunct Therapy*

In the first quarter of the twentieth century, great progress in several fields decreased the risks of serious operations such as hip disarticulation. More careful debridement of wounds was supplemented by chemotherapy and the use of tetanus antitoxin. By the end of World War I, shock occurring in American Army soldiers was treated by fluid replacement and whole-blood transfusion (64).

Knowledge of the physiology and technique of blood transfusion was greatly advanced in the second quarter of the century. Methods of preserving whole blood and plasma were developed, although such problems as the occurrence of homologous-serum hepatitis virus in stored plasma remained unsolved and caused considerable damage. Surgical knowledge of the repair of fractures and of replacement of hopelessly damaged parts of bones by grafts of various types made conservative treatment possible in many more cases than before. The use of sulfa drugs and antibiotics greatly reduced the incidence of infection after severe wounds. Finally, psychotherapeutic measures to prevent psychic trauma and to facilitate re-

covery became an important adjunct to surgical care.

Operative death has become rare (39), but the extent of shock and the resulting damage to the system continue to deserve study.

#### MORTALITY FROM CANCER

Another mortality rate is, however, a matter of much greater concern today. As we have seen, most modern civilian hip disarticulations are performed for cancer. Since at the present time hip disarticulation is commonly not resorted to until other measures (radiation, wide excision) have failed, it often has only a palliative effect. The mortality, if studied for the 5-year-cure rate, is extremely high. Of a series of 52 patients operated upon at the Memorial Cancer Center in New York from 1926 to 1948, 44 (85 percent) died of cancer within five years (39).

Pack (39) and others (11,25,29) have emphasized that, if disarticulation is resorted to only at this late stage, the mortality rate in such cases will continue to be high. In a recent study of patients with malignant disease who underwent hemipelvectomy (an operation comparable to hip disarticulation for the purpose here), Lewis and Bickel (31) observed:

Twelve of the 18 patients who had had symptoms less than six months at the time of operation are still living (two with metastases), and 4 of the 6 who had had symptoms for six months to one year are still living (one with metastases), while only 8 of the 25 patients who had had symptoms for more than one year have survived the present follow-up periods, and one of these has evidence of metastases.

Although there is sometimes justification for disarticulation as a palliative measure, it would be much more desirable to employ it as a cure. Disarticulation as a curative measure will, however, be possible only when surgeon and patient alike are willing to take this radical step at an early stage of the disease.

To what extent will hip disarticulation be replaced by the even more drastic operation of hemipelvectomy? Hemipelvectomy is indicated if malignancy (or, for that matter, a severe crushing injury or a suppurative process such as that mentioned on page 8) has involved the tissues proximal to the coxofemoral joint. Leriche (30) went beyond this in 1937 when he

predicted that hemipelvectomy would one day be considered the operation of choice for malignant growths of the upper part of the thigh. Lee and Alt (29) in 1953 compared hip-joint disarticulation with hemipelvectomy from the point of view of anatomy and surgical technique, extent of postoperative disability and use of prosthesis, and therapeutic effectiveness. They found that under modern conditions there was no great difference between the two operations so far as surgery or postoperative disability are concerned, whereas hemipelvectomy definitely offered better hope of a cure. They therefore considered hemipelvectomy the procedure of choice for high-grade soft-tissue or osteogenic malignant tumors of the upper thigh as well as of the pelvis.

Not all modern surgeons go so far as this. Coley (11) has emphasized that it is essential to discriminate between cases, the decision depending upon the site and grade of malignancy of the tumor. Osteosarcomas and chondrosarcomas of the lower fourth of the femur do not call for hip disarticulation and are better treated by high thigh amputation, since then considerably less disability results.

In sum, allowing a wider margin between the tumor and the incision is now generally recognized to be necessary to ensure elimination of all malignant cells. This means that the level of amputation has tended to move in a proximal direction. While some hip disarticulations have been replaced by hemipelvectomy, high thigh amputations have also been replaced by hip disarticulation, so that no appreciable decrease in the number of hip disarticulations is to be expected as a result of this trend.

#### SURGICAL FASHIONING OF STUMPS

The surgical techniques of hip disarticulation practiced today have evolved as a result of this many-faceted experience. Throughout the history of the operation, the sequence of procedures has been dictated primarily by cumulative experience in combating hemorrhage and shock. The shape of the resulting stump has been affected primarily by the change in indication for the operation from predominantly traumatic to predominantly malignant cases. To a lesser degree, the shape

has been affected by considerations of healing and subsequent fitting with a prosthesis.

#### THE LARGE SOFT-TISSUE STUMP

The large soft-tissue stump popular during the early history of hip disarticulation (Fig. 2) may originally have been developed through association with a high-thigh stump. Surgeons first experimenting with the dangerous operation of hip disarticulation may well have been loath to cut away too much soft tissue. But many of the early operations were actually done by first performing a circular high thigh amputation and then disarticulating the head of the femur through a lateral incision (21,49,61).

During the latter half of the nineteenth century, many experiments were carried out with various kinds of subperiosteal amputations, in which a cuff of periosteum was left overlapping the end of the bone stump. Difficult as it was to perform, a subperiosteal hip disarticulation was done several times. Originally devised by Oilier of Lyons in 1859, it was carried out by James Shuter (50) of London in 1881. A circular amputation was first performed at the junction of the middle and upper thirds of the thigh. The vessels were ligated, and through a longitudinal incision on the lateral aspect of the thigh the remaining portion of the femur was dissected out, leaving the periosteum (peeled off up to the intertrochanteric line) in the flaps.

The advantage of this method, according to Shuter and others who observed the patient over a year after operation, was that the residual periosteum provided a point of attachment for the muscles and caused a growth of what Shuter termed "new bone" but which other observers described as "a firm resisting cord" (50, p. 89), cartilaginous rather than bony in character. Observers testified that this "cord" provided such a good attachment for the muscles that they were "in a high state of nutrition" and that the patient not only could flex, extend, adduct, and abduct the stump powerfully but also could communicate all these movements to the artificial limb. Durand (13) of Lyons had a woman patient who, more than four years after a similar operation, had a regenerative process resembling a tough

fibrous stalk, which also provided an excellent attachment for the muscles. She was able, he stated, to lift a weight of 15 kg. with her flexed stump.

In a modern case (24) the patient, although apparently not operated upon subperiosteally, was said to have had a stump with many of the characteristics claimed for the subperiosteal stumps. Disarticulation was done for osteomyelitis of the femoral shaft, trochanter, and neck, a sequel to extensive injuries of the thigh. The femur was carefully dissected out from the surrounding tissues, leaving a soft-tissue stump measuring 6 in. when relaxed. It was reported that "The muscles had become attached to each other by scar tissue, so that there was active flexion and extension of the stump if one grasped the muscles with his hands." The patient was able to wear a suction-socket prosthesis, which he could flex and extend at the hip joint "because of the fixation of the skin and muscles to the side of the socket by the suction exerted upon the distal end of the stump." This method of activating the prosthesis was compared to that used by crustaceans in activating their exoskeletons, and a point was made of the importance in this case of designing the socket so that, upon weight-bearing, the contracted muscle mass would be properly positioned on the ischial seat beneath the ischial tuberosity.<sup>6</sup>

About the turn of the century, subperiosteal amputations were gradually abandoned, mainly because of the frequency of undesirable growths of new bone emanating from the periosteal cuff. Apparently only a few subperiosteal hip disarticulations were performed. In addition to the uncontrollability of new bone growth, other, even more important, reasons prevented the operation from becoming popular. One was the difficulty of stripping the periosteum from a healthy bone. Shuter's subperiosteal operation was done for a suppurative process of the femur, in the course of which the periosteum had already achieved a considerable degree of natural separation from the bone. Durand did not mention a similar condition in his patient, but his operation was done

<sup>6</sup> Cf. discussion of very short thigh stumps, page 15.

for tuberculosis, and possibly a suppurative process was present. Another reason, much more significant today, was that the retention of the periosteum made the procedure unsuited for any disarticulation done because of a malignant neoplasm.

#### THE COMPACT STUMP

After disarticulation for malignancy, the hip stump commonly fashioned today is compact, with the soft tissues reduced to a minimum. When involvement of the inguinal nodes is proved, or, in certain disease, even suspected, a radical groin dissection is also done, thus removing even more tissue from the body.

Most incisions today, whether of the anterior racquet or semioval type, start just below the inguinal ligament and thus provide immediate access to the femoral vessels and nerve in Scarpa's triangle. These incisions create a long posterior flap and leave an anterior scar that is well removed from terminal and lateral pressure areas and from any possibility of fecal contamination before wound-healing is complete. The semioval incision has the advantage of eliminating the "handle" of the racquet, which, if carried too far, may easily invade a pressure area under the pelvic corset of the prosthesis. For this reason, it would seem to be the incision of choice for the use of the Canadian-type hip-disarticulation prosthesis, as may be seen from Figure 11, page 37. This prosthesis is, however, very adaptable and can easily be modified to accommodate a larger or smaller amount of soft tissues (even dog-ears). Bony prominences are not necessary to anchor it. If the wound has healed by first intention, it is no longer critical whether the scar lies under a pressure area.

For further information on the modern technique of hip disarticulation, the reader is referred to Slocum's procedure, which is detailed on pages 242-244 of his work, *An Atlas of Amputations* (51). The muscles are sectioned in the avascular areas close to their tendinous origins or insertions. Some additional precautions against shock, as already discussed, may be found desirable in certain cases. For cases in which involvement or suspected involvement of the inguinal nodes necessitates radical groin dissection, Pack and Ehrlich's

standard method (40) can be followed. A racquet incision, with the handle of the inverted Y extending proximally, is recommended for this procedure, which is carried out before the hip disarticulation. The only problem here is that the large skin flaps, denuded of all underlying subcutaneous fat, lymphatic tissue, and fascia, are susceptible to necrosis and sloughing along their edges. Not much can be done about this, since in order to be effective the procedure has to be thorough. Since the wound does not ordinarily heal by first intention, the scar, extending as it does well above the line of the inguinal ligament, may present problems in the fitting of the Canadian-type hip-disarticulation prosthesis.

#### POSSIBILITY OF SHORT THIGH STUMP

Most cases of malignancy, as we have seen, require radical removal not only of the bone but also of as much soft tissue as possible. When the amputation follows trauma or disease other than cancer, however, the question may arise as to whether to disarticulate or to leave a very short thigh stump. The improvement of artificial limbs, as well as of surgical techniques, has made it possible to fit above-knee amputees of higher and higher amputation level with thigh prostheses rather than with hip-disarticulation prostheses. In 1930, Verrall (66) stated that any stump measuring less than 5 in. below the greater trochanter had to be fitted with a tilting-table (hip-disarticulation) prosthesis. In 1949, Slocum stated (51, p. 402) that "When amputation approaches the level of the lesser trochanter, the function of this [hip] joint is nullified ..." and that therefore a patient with an amputation at this level or higher had to be fitted with some type of hip-disarticulation prosthesis. The possibility of fitting a suction socket depends, however, not only on the length of the residual bone but also on the volume of the soft tissues which provide the seal for holding suction. Indeed, in the case of the man with a completely boneless stump (cf. p. 14), the soft tissues alone enabled him to wear a suction-socket prosthesis.

The leverage provided by even a small segment of the femur is, of course, a great advantage in activating a prosthesis. Tikhonov

(59) reported interesting experiments to lengthen a short residual femur by bone grafts. He said that it was not possible to give an absolute measurement for the shortest thigh stump which could activate a thigh prosthesis, since this length depended also on the volume of soft tissues, which varied from stump to stump. Instead, he gave a formula based on the relation of length to circumference. He also noted that except for extreme cases a stump should measure somewhere between 8.5 and 13.5 cm. (3.3 and 5.3 in.) from the perineum in order to allow for piston action of 2 to 3 cm. (about an inch) yet still permit the prosthesis to be moved in any direction. For the patient with other handicaps in addition to the very short thigh stump (such as amputation of the contralateral extremity or an upper-extremity amputation), Tikhonov and his co-workers recommended that surgical lengthening of the short stump be considered as a means of increasing the patient's ability to get about.

Tikhonov reported on the lengthening of three short thigh stumps by from 3 to 6 cm. (1.2 to 2.4 in.). A homoplastic graft, taken from the diaphysis of the fibula, was inserted into the medullary canal of the femur. After a maximum period of observation of 10 months, he reported that bony union had already been achieved in two of the lengthened stumps and that these were providing satisfactory additional leverage for activating a prosthesis.

#### POSSIBLE SYSTEMIC EFFECTS OF MAJOR LOSS OF LIMB

As more patients have survived these drastic operations and have become subjects for rehabilitation, increasing attention has been paid to the possible medical consequences of the loss of so large a part of the body. The entire limb can now be removed without great risk of operative death, the patient can be fitted successfully with a prosthesis, and appropriate attention can be given to his psychological and vocational readjustment. Then this question arises: What is the *medical* outlook for such a patient? The same kind of question has been raised in regard to many diseases and disabilities to which corrective measures have been applied. Frequently, all of the medical

consequences of a selected course of therapy cannot be foreseen. The physician asks himself: Am I doing the right thing? Will the radiation therapy that appears so beneficial now give rise to untold medical harm later?

In the recent literature of several European countries, there have been raised questions about possible systemic aftereffects of major amputation which could hold much significance for the rehabilitation of amputees. The answers have proved difficult. Many of the opinions expressed have been supported only by clinical impressions or by studies lacking in desirable controls. Many have been accompanied by enthusiastic but untested hypotheses. It appears that, before this mass of information can be evaluated properly and before definitive answers can be obtained, the questions may need to be rephrased and made the subject of carefully controlled studies.

In their examinations of amputees, many physicians have observed signs and symptoms and have obtained in clinical tests results which have led them to suspect that amputation is followed by an increased incidence of systemic disease. The review of published observations made by Schulze in Germany in 1942 shows that major limb amputations had at that time already been thought capable of leading to a rather startling list of disorders, including obesity, abnormally increased perspiration, arteriosclerosis, enlargement of the heart, damage to the heart muscle, hypertension, pulmonary tuberculosis, aggravation of bronchial asthma, various disturbances of the digestive system, kidney disease, deformities of the healthy leg and foot, joint deformities, and worsening of varicose veins (48, pp. 72-73). Some of these conditions are more likely to occur after major amputation than are others. Aside from further changes in the musculoskeletal system, the most frequently claimed effects have been cardiovascular disease—especially hypertension—and changes in the regulation of body heat—in particular, excessive perspiration. German authors have advanced hypotheses to explain the development of these clinically observed phenomena.

Sturm appears to have been interested in these problems since 1940 and has published recently, with two colleagues (57), a report of

detailed clinical studies on 150 amputees. Of these patients, 130 were at Bad Nenndorf for a "cure." Medical histories were elicited from them by means of a questionnaire and were amended through interview and examination. In addition, various tests of cardiovascular function were made, with amputees appropriately grouped, in order to show that the incidence of cardiovascular abnormalities increases with the length of time since amputation. In an earlier paper, Sturm (56) described a syndrome characteristic of a few patients with long-standing amputations of the thigh and with a history of severe suppuration of the stump. Examination of such a patient showed a pale angiospastic face, a definite lability of pulse rate and blood pressure, marked dermographism, increased reflex activity, fine tremor of the hands, moist skin, and increased luster of the sclera. Most of Sturm's observations were offered in support of his hypothesis that "vegetative regulatory disturbances" in amputees result from chronic hypothalamic irritation, which in turn arises (by a stated neurophysiological mechanism) from prolonged infection, pain, and vasoconstriction of vessels of the stump.

Schneider (46), who observed an increase of systolic pressure to over 140 mm. Hg in 20 percent, and of diastolic pressure to over 100 mm. Hg in 5 percent, of 67 amputees, developed Sturm's thesis further. He hypothesized that pain (triggered by a neuroma, long-lasting suppuration, deep-tissue scars, or even the pressure of the prosthesis) could, in constitutionally predisposed patients, excite the central sympathetic area of the hypothalamus and eventually create a central lesion with resulting hypertonia. Schneider also pointed out that the role of psychosomatic factors should not be underestimated. The frustration and resulting emotional conflicts experienced by amputees who were attempting to compete with normal individuals could contribute to an early development of essential hypertension.

Another hypothesis concerns the heat-regulating mechanism of the body and the changes which result in it from the loss of a leg. Excessive perspiration in high-thigh and hip-disarticulation amputees has been frequently observed on a clinical basis. Schroder (47) com-

mented on the role played by the extremities in the cooling system of the body in providing arteriovenous shunts to direct the flow of blood into deep or superficial vessels as needed and in providing a large surface area for evaporation. To him, the loss of a whole lower extremity would appear to mean the loss of a valuable part of the cooling system at the same time that extra demands on energy are being made, with resulting excessive production of heat. Such phenomena would indicate an unusual burden on the circulatory system.

These views have excited interest and aroused controversy. Although clinicians may observe in amputees pathological conditions which strongly suggest themselves to be the aftereffects of amputation, analyses of government health records, and clinical studies based on them, have failed thus far to confirm these observations in amputees as compared with equivalent nonamputee populations.

The difficulties of assessing the aftereffects of amputation are well reflected in the reports, annotated in *Lancet* (16,38), of the committee of the Ministry of Pensions in England which in 1950 was asked to find whether amputation of a limb, and subsequent wearing of a prosthesis, could initiate or aggravate cardiovascular disorder and whether such amputation reduces the expectation of life. The interim report of this committee in 1951, termed "somewhat inconclusive," revealed in living amputee pensioners a slight elevation of the mean blood pressure but no abnormal incidence of cardiovascular disease. A more detailed study of death certificates suggested, although not to the point of statistical significance, that patients with leg amputations died earlier, and more commonly from cardiovascular disease, than comparable pensioners with leg wounds not requiring amputation. The majority report of the committee in 1953 introduced a new factor—calling for further committee investigation—by suggesting that men who have suffered major sepsis, with or without amputation, have a higher late incidence of cardiovascular disease and an earlier average death. The committee then arranged for the medical examination of 5500 pensioners, of whom 4500 were to be amputees and 1000 were to be controls, but unfortunately so many of this sample

"failed to attend" that no firm conclusions could be drawn. In 1955, however, the committee, after reviewing all of its evidence, made the following statement (38):

Limb amputations, and the subsequent wearing of a prosthesis do not, in time, produce effects on the body as a whole which may initiate, or aggravate, cardiovascular disorders to any significant extent. There is no material difference between the mortality rates of amputees, by reason of amputation, and that of the corresponding rates for pensioners who have suffered wounds not leading to amputation. Such excess as there is in both classes over that in the general population is quite small.

For the German regional government of Schleswig-Holstein, Meyeringh and Stefani (35) sought to determine the incidence of hypertension in 794 above-knee amputees. They found a resting systolic blood pressure of over 150 mm. Hg in 9 percent, which they compared with an incidence of over 10 percent in the "average German population."

In reviewing the articles pertinent to this controversy, one begins to suspect that a single careful distinction might do much to resolve it. This distinction would be between (*a*) asserting that systemic disease does occur in amputees and is due at least in part to the fact of amputation and (*b*) asserting that systemic disease occurs more frequently in amputees than in other persons. Conceivably, the same person who develops high blood pressure owing to physiological stresses imposed by amputation could also have developed high blood pressure for different reasons of physiological stress had he retained his leg. Whereas this explanation would seem too simple, it is not too difficult to imagine a complex of factors at work that could mask from certain types of statistical examination a true relation between amputation and subsequent disease.

It would seem a pity should too much energy be expended in statistical quibble. The question of relative incidence of systemic disease in amputees and in normals is an important question for practical reasons—such as life insurance, pensions, and the allotment of research funds. Of more moment, however, to researcher, practitioner, and amputee alike, is the question of how and why systemic disease develops in amputees and whether it can be

averted in rehabilitation. Furthermore, far from being dispensable, statistical analyses of data obtained from groups of amputees and from appropriate control groups would be a tool valuable to this elucidation.

Many factors offering clues to the situation have been taken into consideration to a greater or lesser extent by individual authors—pre-disposition to hypertension, prolonged sup-puration associated with amputation, difference in level of amputation or amount of body mass lost, age at amputation, and obesity. Owing to the differences—or obscurities—regarding the selection of subjects, the use of controls, and the criteria for systemic disease, the results of these authors cannot be compared satisfactorily or generalized. The possible importance of activity or inactivity, the wearing of a prosthesis, and the stresses attached to home and work environments has hardly begun to be considered from the medical viewpoint of systemic disease! Investigation into the systemic effects of amputation could lead to conclusions beneficial not only to amputees with hip disarticulations and high thigh amputations but also to amputees with less serious disabilities and even to persons suffering from other disorders.

#### SUMMARY

Hip disarticulation is a drastic amputation used almost exclusively as a last-resort or life-saving measure. A review of the medical history of the operation during the last 200 years shows a number of changes. The one with the most far-reaching implications has been the major shift from operations indicated by injury or by disease other than cancer to operations indicated by malignant growth. Better methods for controlling hemorrhage and shock, together with progress in adjunct therapy, have reduced operative deaths from as high as 91 percent in pre-Civil War military cases to none in a recent American series done for malignancies. But the postoperative mortality in cancer cases continues to be extremely high (in the aforementioned recent series, 85 percent within five years of operation). For this reason some hip disarticulations, when indicated at all for cancer, may well be indicated much earlier in the course of the disease

if the operation is to be therapeutic rather than merely palliative.

The shift in indication has also influenced the surgical shaping of the stump to the extent that today, in contrast to earlier methods, a maximal removal of soft tissues as well as bone is considered essential in cases of malignancy. In the rarer cases in which the indication for operation is trauma or some other type of disease, it is advantageous to leave, whenever possible, a small segment of the femur and additional soft tissues in the stump, thus making possible the use of an above-knee rather than a hip-disarticulation prosthesis. With the Canadian-type hip-disarticulation prosthesis, the shape of the stump is not critical, because this device can readily accommodate any irregularities of body form.

Whether disturbances of cardiovascular function, or of other functions such as thermoregulation, occur as a result of the loss of so large a part of the body is today a controversial subject. Although systemic disease has been noted frequently in amputees with major loss of limb, no controlled studies have demonstrated convincingly that the incidence of systemic disease is greater in amputees than in comparable nonamputees. Similarly, hypotheses that have been advanced to explain how systemic disease develops as a result of amputation are interesting but still without substantial verification physiologically. This area should be an attractive one for further research.

#### ACKNOWLEDGMENT

The author wishes to express his gratitude to the many members of the Biomechanics Laboratory whose generous help and cooperation made this paper possible. A particular debt is owing to our staff writer, Jean C. Lieberman, Ph.D., who was responsible for much of the historical research basic to the paper and for assistance in its composition.

#### LITERATURE CITED

1. *An account of the operation of amputating the thigh at the upper articulation, lately performed by Mr. William Kerr, Surgeon to the Royal Regiment of Horse-Guards Blue, and to the Hospital in Northampton.* Communicated to Dr. Duncan, by Dr. Toll, Surgeon to the Fourth Regiment of Dragoons, M. & Philos. Commentaries, 6:337 (1779).
2. Angerer, H., *Ein einfaches Vorgehen zur Verringerung der Operationsgefahr bei Exartikulationen im Hüft- und Schullergelenk*, Zentralbl. Chir., 69:1647 (1942).
3. Beebe, Gilbert W., and Michael E. DeBakey, *Battle casualties: incidence, mortality, and logistic considerations*, Thomas, Springfield, Ill., 1952.
4. Bolot, F., and P. Merz, *Disarticulation de la hanche pour un osteosarcome du fémur ayant envahi les parties molles et provoque une hémorragie grave*, Maroc. med., 31:560 (1952). (Only title seen.)
5. Boyd, Harold B., *Anatomic disarticulation of the hip*, Surg., Gyn., & Obstet., 84:346 (1947).
6. Brooks, Barney, *Exarticulation of the hip joint; with preliminary ligation of the common iliac artery*, J.A.M.A., 76:94 (1921).
7. Bustos, Fernando M., *Desarticulacion coxofemoral (profilaxis del shock por seccion primaria del cédico)*, Bol. y trab. Acad. argent. cir., 32:195 (1948).
8. Callander, C. Latimer, *A new amputation in the lower third of the thigh*, J.A.M.A., 105:1746 (1935).
9. Caprio, Gerardo, *Grandes desarticulaciones en la raíz de los miembros*, Bol. Soc. cir. Uruguay, 22:518 (1951).
10. Coates, John Boyd, ed., *Orthopedic surgery in the European Theater of Operations*, Office of the Surgeon General, Dept. of the Army, Washington, D. C., 1956.
11. Coley, Bradley L., *Neoplasms of bone*, Hoeber, New York, 1949.
12. DeBakey, Michael E., and Fiorindo A. Simeone, *Battle injuries of the arteries in World War II*, Ann. Surg., 123:534 (1946).
13. Durand, M., *De la disarticulation sous-periostee de la hanche et de ses avantages sur la methode ordinaire*, Rev. chir., Paris, 17:646 (1897).
14. Farabeuf, [L. H.], *Communication orale sur la disarticulation coxo-femorale*, Bull. et mem. Soc. de chir., 4:180 (1878).
15. Farabeuf, L. H., *Precis de manuel operatoire*, 4th ed., Masson, Paris, 1893-1895. pp. 648-678.
16. *The fate of the amputee* (Annotation), Lancet, 1:633 (1953).
17. Ghitzesco, C. I., *La disarticulation de la hanche sous l'hémotase provisoire de l'artere iliaque primitive ou de l'hypogastrique correspondante*, Presse meU, 43:243 (1935).
18. Giles, Roscoe C., and William T. Keig, *The control of bleeding in disarticulation of the hip by ligation of the common iliac artery and vein*, Illinois Med. J., 106:209 (1954).
19. GÜlis, Leon, *Amputations*, Heinemann, London, 1954.
20. Grey, Jorge de Moraes, *Actinomicose do membro inferior e desarticulacao da coxa. Consideracoes clinicas e technicas em torno de duas desarticulacoes da coxa*, Rev. brasil. cir., 11:159 (1942).



21. Gross, S. D., *Report of the committee on surgery*, Trans. Kentucky State Med. Soc., 2:99 (1853).
22. Halsted, W. S., *The effect of ligation of the common iliac artery on the circulation and function of the lower extremity. Report of a cure of ilio-femoral aneurism by the application of an aluminum band to that vessel*, Bull. Johns Hopkins Hosp., 23:191 (1912).
23. Huard, P., *Etudes sur les amputations et disarticulations des membres*, Masson, Paris, 1940.
24. Hutter, Charles G., *Suction-socket prosthesis for a hip-disarticulation amputee*, J. Bone & Joint Surg., 35A:230 (1953).
25. James, Arthur G., and Wesley Furste, *Radical surgery for cancer of the extremities*, Am. J. Surg., 85:503 (1953).
26. Katz, Elias, Private communication.
27. Kirk, Norman T., and Leonard T. Peterson, *Amputations*, Chapter 10 in Lewis' *Practice of surgery*, Prior, Hagerstown, Md., 1944. Vol. 3, pp. 84-87.
28. Larrey, Dominique Jean, *Memoires de chirurgie militaire, et campagnes*, J. Smith, Paris, 1812. Vol. 2, pp. 180-195. Vol. 3, p. 350.
29. Lee, C. Marshall, Jr., and Lewis P. Alt, *Hemipelvectomy and hip disarticulation for malignant tumors of the pelvis and lower extremity*, Ann. Surg., 137:704 (1953).
30. Leriche, Rene, *A propos de 13 cas de disarticulation de la hanche*, Mem. Acad. chir., 63:1435 (1937).
31. Lewis, Royce C., and William H. Bickel, *Hemipelvectomy for malignant disease*, J.A.M.A., 165:8 (1957).
32. McBurney, Charles, *Direct intra-abdominal finger-compression of the common iliac artery during amputation at the hip-joint*, Ann. Surg., 25:610 (1897).
33. Marquardt, Wolfgang, *Gliedmassenamputationen und Gliederersatz*, Wissensch. Verlagsges., Stuttgart, 1950. pp. 82-85.
34. Maynard, R. L., *Hip-joint disarticulations*, Trans. New England Surg. Soc., 24:248 (1941).
35. Meyeringh, H., and H. Stefani, *Besteht nach einer Amputation des Oberschenkels eine Neigung zur Adipositas und zur Hypertension?*, Deutsche med. Wchnschr., 81:10 (1956).
36. Morand, Sauveur Francois, *Opuscules de chirurgie*, Desprez, Paris, 1768. Vol. 1, pp. 176-228.
37. Morris, Robert T., *Hip joint amputation, ventral hernia, appendicitis, salpingitis, a clinic at the New York Post Graduate Medical School April 18, 1917*, West. M. Times, 37:1 (1917).
38. *Outlook for the amputee* (Annotation), Lancet, 1:89 (1955).
39. Pack, George T., *Major exarticulations for malignant neoplasms of the extremities: interscapulothoracic amputation, hip-joint disarticulation and interilioabdominal amputation*, J. Bone & Joint Surg., 38A:249 (1956).
40. Pack, George T., and Harry E. Ehrlich, *Exarticulations of the lower extremities for malignant tumors: hip joint disarticulation (with and without deep iliac dissection) and sacro-iliac disarticulation (hemipelvectomy)*, Ann. Surg., 123:965 (1946). Parts I & II.
41. Petrovskii, B. V., *Method of disarticulation of the hip*, Vestnik khir., 72:50 (1952). In Russian.
42. Piquinela, Jose A., *Desarticulacion de cadera.—Su tecnica de acuerdo con los principios del metodo de Callander*, Arch. urug. med., 48:191 (1956).
43. Pitkin, George P., *Conduction anesthesia*, 2nd ed., James L. Southworth, Robert A. Hingson, and Winifred M. Pitkin, eds., Lippincott, Philadelphia, 1953.
44. Richerand, cited in 60, p. 8.
45. Saltzstein, Harry C., *Osteogenic sarcoma of upper third of femur; well ten years after disarticulation at the hip joint*, J. Michigan Med. Soc., 43:145 (1944).
46. Schneider, K. W., *Zur Frage der Plethora und Hypertonie bei Amputierten*, Klin. Wchnschr., 31:697 (1953).
47. Schroder, Joachim, *Zur Frage einer besonderen Kreislaufbelastung bei Gliedmassenamputierten infolge einer Mehrbeanspruchung ihrer Wärmeregulation*, Deutsche med. Wchnschr., 81:1620 (1956).
48. Schulze, Karl, *Über den Einfluss grosser Amputationen auf den Gesamtorganismus; eine Studie zur Frage der Spatschaden bei Oberschenkelamputierten*, Arbeit u. Gesundh., No. 41:69 (1942).
49. [Shuter, James], *Subperiosteal amputation at the hip-joint*, Report of Clinical Society of London, Brit. Med. J., 1:314 (1883).
50. Shuter, James, *Subperiosteal amputation at the hip-joint: formation of new bone in the stump: moveable stump: patient wearing an artificial limb*, Trans. Clin. Soc. London, 16:86 (1883).
51. Slocum, Donald B., *An atlas of amputations*, Mosby, St. Louis, 1949. pp. 239-247, 402-410.
52. Smith, Beverly Chew, *Disarticulation of the hip for endothelioma (Ewing's tumor): 31-year follow-up*, Ann. Surg., 115:318 (1942).
53. Smith, S., *Statistics of the operation of amputation at the hip-joint*, New York J. Med., 9:184 (1852).
54. Stajano, C., *El mecanismo del "choc" en la desarticulacion de la cadera*, Arch. urug. med., 10:642 (1937).
55. Strauss, Kurt, *Exarticulatio coxae bei Schwangerschaft und allgemeiner Sepsis*, Miinchen. med. Wchnschr., 86:1751 (1939).
56. Sturm, Alexander, *Hochdruck nach Oberschenkelamputation*, Med. Klin., 48:197 (1953).
57. Sturm, A., W. Frisch, and H. W. Griinewald, *Interne Auswirkungen von Beinamputationen; Ergebnis einer Reihenuntersuchung*, Medizinische, No. 35:1132 (1954).
58. Thomson, John, *Report of observations made in the British military hospitals in Belgium after the Battle of Waterloo*, Blackwood, Edinburgh, 1816. pp. 259-279.
59. Tikhonov, V. M., *Short thigh stump in children, its lengthening and preparation for prosthesis*, Tr.

- Tsentr. Nauchnoissledov. inst. protez. Moskva, 72:258 (1949). In Russian.
60. Tixier and Arnulf, *Auto-transfusion au cours d'une desarticulation de la hanche, en utilisant le sang du membre enleé. Disarticulation pour epithelioma developpt sur une ancienne brulure de la cuisse et de la /esse jusqu'd Vanus; anus de Pollosson (derivation totale) prealable*, Lyon chir., 32:443 (1935).
  61. Trendelenburg, F., *Ueber Exarticulation des Oberschenkels*, Arch. klin. Chir., 26:858 (1881).
  62. U. S. Surgeon General's Office, *Circular No. 7: a report on amputations at the hip-joint in military surgery* [By G. A. Otis], U. S. Gov't. Print. Off., Washington, D. C, 1867.
  63. U. S. Surgeon General's Office, *The medical and surgical history of the War of the Rebellion (1861-1865)*, U. S. Gov't. Print. Off., Washington, D. C, 1870-88. Part 3, vol. 2: *Surgical history*. pp. 88, 89, 127-168.
  64. U. S. Surgeon General's Office, *The Medical Department of the U. S. Army in the World War*, U. S. Gov't. Print. Off., Washington, D. C, 1921-1929. Vol. II, *Surgery*, Part 1 (*General surgery, orthopedic surgery, neurosurgery*).
  65. Velpeau, Alf. A. L. M., *New elements of operative surgery*, 1st American ed., from last [2nd] Paris ed. [1839], translated by P. S. Townsend, under supervision of Valentine Mott, S. S. & W. Wood, New York, 1847. Vol. 2, pp. 637-653.
  66. Verrall, P. Jenner, *Some amputation problems*, Proc. Roy. Soc. Med., 24:183 (1930).
  67. Wyeth, John A., *Bloodless amputation at the hip joint*, New York Med. J., 61:528 (1890).